

Research Paper  
Reconstructive Surgery

# Three-dimensional morphological analysis of neocondyle bone growth after fibula free flap reconstruction

Y. Yu, H. Y. Soh, S. Bai,  
W.-B. Zhang, Y. Wang, X. Peng  
Department of Oral and Maxillofacial Surgery,  
Peking University School and Hospital of  
Stomatology, Beijing, China

Y. Yu, H.Y. Soh, S. Bai, W.-B. Zhang, Y. Wang, X. Peng: *Three-dimensional morphological analysis of neocondyle bone growth after fibula free flap reconstruction. Int. J. Oral Maxillofac. Surg. 2021; 50: 1429–1434.* © 2021 International Association of Oral and Maxillofacial Surgeons. Published by Elsevier Inc. All rights reserved.

**Abstract.** The aim of this retrospective study was to verify the three-dimensional morphological change in neocondyle bone growth after fibula free flap (FFF) reconstruction. The independent variables were age, sex, and diagnosis. Outcome variables included the direction and volume of neocondyle bone growth, and the time to a stable neocondyle following bone growth. The outcome variables were measured on postoperative computed tomography scans using iPlan 3.0. Of the 35 patients included, 25 showed neocondyle bone growth. The direction of neocondyle bone growth included the direction of lateral pterygoid traction (DLPT) and the direction towards the glenoid fossa (DGF). The bone growth of the neocondyle showed three patterns: only DLPT (eight patients), only DGF (two patients), and a combination of DLPT and DGF (15 patients). The average volume of bone growth in the 25 patients was  $0.479 \pm 0.380 \text{ cm}^3$ . The average volume of neocondyle bone growth was significantly greater in patients aged  $<18$  years ( $0.746 \pm 0.346 \text{ cm}^3$ ) than in patients aged  $>18$  years ( $0.219 \pm 0.191 \text{ cm}^3$ ) ( $P < 0.001$ ). The time to a stable neocondyle following bone growth was 5.6 months postoperatively. In conclusion, neocondyle bone growth after FFF reconstruction occurred in two different directions, DLPT and DGF. Osteogenesis of the lateral pterygoid muscle affects neocondyle growth with DLPT. Neocondyle bone growth is more marked in paediatric patients than in adults.

Key words: mandibular reconstruction; fibula; osteogenesis; pterygoid muscle; ankylosis.

Accepted for publication 5 March 2021  
Available online 19 March 2021

Mandibular reconstruction is a challenging task in head and neck reconstructive surgery, which aims to achieve the best possible functional and aesthetic outcomes. In 1989, Hidalgo demonstrated

the utility of the vascularized fibula free flap (FFF) for mandibular reconstruction<sup>1</sup>. Since then, the FFF has become a highly reliable and popular flap for mandibular reconstruction<sup>2</sup>. This flap has

many advantages, including a long pedicle length, wide vessel diameter, and the ability to incorporate skin, muscle, and bone components, which are required for mandibular reconstruction<sup>3</sup>.

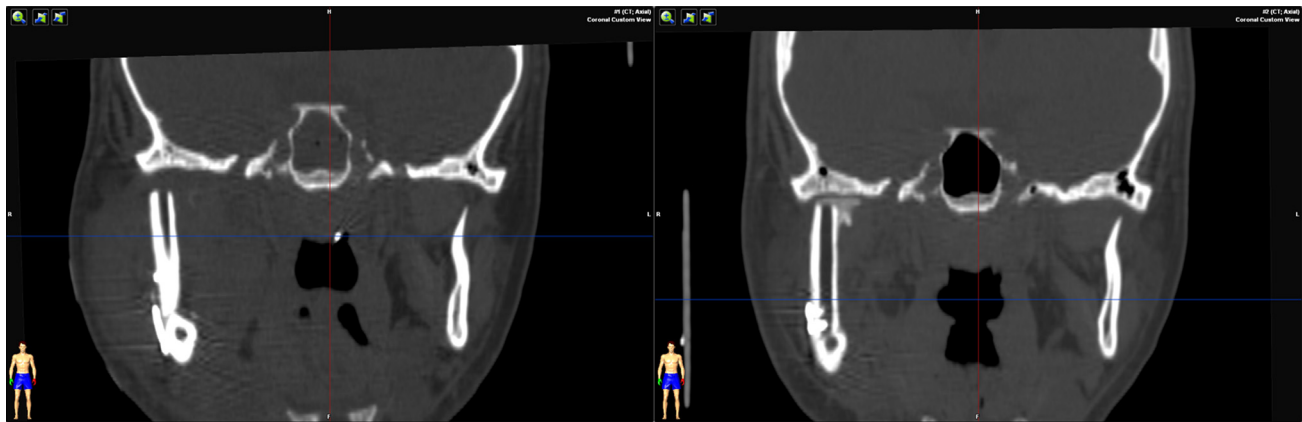


Fig. 1. Compared with the 1-month postoperative CT examination (left), the 3-month postoperative CT shows neocondyle bone growth (right).

A mandibulectomy that includes the condyle may be performed in patients with osteomyelitis, trauma, or a tumour. Several techniques have been used to reconstruct the mandibular condyle, including the autogenous costochondral graft, autogenous coronoid process, distraction osteogenesis, vertical ramus osteotomy, total alloplastic joint prosthesis, and vascularized free tissue transfer for reconstruction. Vascularized fibula flaps allow the anatomy of the mandibular ramus and condyle to be rebuilt, but cannot maintain an appropriate condyle–disc relationship during mandibular movement. A previous study performed at the authors' institution demonstrated that the two different neocondyle repositioning patterns were associated with the morphology of the neocondyle<sup>4</sup>. Some studies have found that neocondyle remodelling can result in persistent postoperative trismus and postoperative temporofibular ankylosis<sup>5–7</sup>. In fact, neocondyle bone growth after FFF reconstruction remains unclear. The aim of this study was to verify the three-dimensional (3D) morphological changes in the neocondyle.

## Materials and methods

The study population was composed of patients who had undergone a mandibulectomy that included the condyle for the treatment of benign or malignant tumours and underwent mandibular reconstruction with a FFF at Peking University School and Hospital of Stomatology between January 2013 and June 2016. The inclusion criteria were (1) stable occlusion before and after surgery, (2) unilateral mandibular defect affecting the condyle, and (3) preserved lateral pterygoid muscle and temporomandibular articular joint discs.

Surgery was performed under general anaesthesia with nasotracheal intubation. Based on the location of the lesion, the mandible was exposed through a submandibular approach with or without a lower lip-splitting incision, and the lateral pterygoid muscle and temporomandibular joint (TMJ) disc were carefully preserved. After mandibular resection, the FFF was harvested, shaped, and fixed to the residual mandible using miniplates. The distal fibula segment was shaped as the neocondyle and placed in the glenoid fossa. The same chief surgeon (XP) performed the tumour resection and mandibular reconstruction on every patient.

The postoperative maxillofacial computed tomography (CT) scans (with a slice thickness of 1 mm) of each patient were reviewed retrospectively. All patients underwent postoperative scans at 3-month intervals during the first year after surgery, which could show any new bone formation in relation to the fibula neocondyle (Fig. 1). The postoperative CT data

were imported into iPlan 3.0 (Brainlab, Feldkirchen, Germany). 3D virtual models of the maxillofacial skeleton and the lateral pterygoid muscle from every postoperative CT scan were created according to different CT attenuations. The different 3D models of the neocondyle were registered using the same coordinate system, which helped to verify morphological changes and the time to a stable neocondyle following neocondyle remodelling. The morphological changes of neocondyle remodelling between the initial neocondyle and stable neocondyle were marked to produce the distinct 3D model, while the volume of the marked 3D model was automatically acquired by the iPlan 3.0 software.

Correlation analysis between the primary independent variables, other independent variables, and the primary outcome variable was performed using SPSS Statistics version 17.0 (SPSS Inc., Chicago, IL, USA). Statistical significance was set at  $P \leq 0.05$ .

Table 1. Descriptive statistics of the study sample.

|  |               |
|--|---------------|
| Number of patients                                       | 35            |
| Sex  |               |
| Female   | 18            |
| Male   | 17            |
| Mean age (years)   | 32.3 ± 17.5   |
| Diagnosis  |               |
| Benign   | 28            |
| Malignant  | 7             |
| Temporofibular ankylosis                                 | 0             |
| Mean follow-up period (months)                           | 21.8 ± 9.9    |
| New neocondyle formation                                 | 25            |
| Only DLPT  | 8             |
| Only DGF   | 2             |
| DLPT + DGF   | 15            |
| Mean volume of neocondyle bone growth (cm <sup>3</sup> ) | 0.479 ± 0.380 |

DLPT, new bone formed in the direction of lateral pterygoid traction; DGF, new bone formed in the direction of the glenoid fossa. Data presented as the number, or mean ± standard deviation.

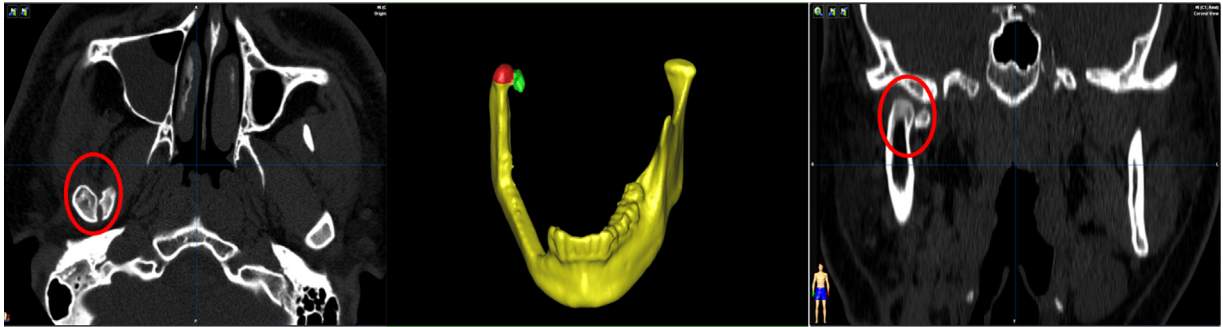


Fig. 2. The red circle shows neocondyle bone growth in the direction of lateral pterygoid traction (DLPT; right) and in the direction of the glenoid fossa (DGF; left). Three-dimensional models of neocondyle bone growth in the DGF and DLPT were created.

This study received ethical approval from Peking University School and Hospital of Stomatology (approval number PKUSSIRB-202055073). Further, the protocol was in keeping with the tenets of the Declaration of Helsinki.

## Results

This retrospective case series enrolled 35 patients (18 female, 17 male) with an average age of 32 years (range 8–72 years) who underwent surgical resection of tumours (benign in 28 patients, malignant in seven patients). In most patients, the primary tumour was an ameloblastoma ( $n=18$ , 51.4%). All of the fibula flaps survived after surgery without any complications. The average follow-up time for the 35 patients was  $21.8 \pm 9.9$  months. No patients developed persistent postoperative trismus or postoperative temporofibular ankylosis (Table 1).

Of the 35 patients, 25 showed new bone formation in the neocondyle, while 10 did not. The average volume of bone growth for the 25 patients was  $0.479 \pm 0.380 \text{ cm}^3$ . Neocondyle bone growth occurred in two directions: the direction of lateral pterygoid traction (DLPT) and the direction towards the glenoid fossa (DGF) (Fig. 2). Neocondyle bone growth had

three patterns: (1) DLPT only, which occurred in eight patients (Fig. 3); (2) DGF only, which occurred in two patients (Fig. 4); (3) DLPT + DGF, which occurred in 15 patients (Fig. 2).

The average volumes of neocondyle bone growth, bone growth in the DLPT, and bone growth in the DGF were  $0.479 \pm 0.380 \text{ cm}^3$ ,  $0.183 \pm 0.167 \text{ cm}^3$ , and  $0.446 \pm 0.371 \text{ cm}^3$ , respectively. The average bone growth volume in the DLPT was significantly lower compared with bone growth in the DGF ( $P=0.004$ ) (Table 2). The average volumes of neocondyle bone growth, bone growth in the DLPT, and bone growth in the DGF were significantly greater in patients aged <18 years ( $0.746 \pm 0.346 \text{ cm}^3$ ,  $0.292 \pm 0.197 \text{ cm}^3$ , and  $0.681 \pm 0.407 \text{ cm}^3$ , respectively) than in patients aged >18 years ( $0.219 \pm 0.191 \text{ cm}^3$ ,  $0.107 \pm 0.073 \text{ cm}^3$ , and  $0.237 \pm 0.159 \text{ cm}^3$ , respectively) ( $P < 0.001$ ,  $P = 0.001$ , and  $P < 0.001$ , respectively) (Table 3).

For two patients, bone growth in the DLPT was associated with bone growth in the DGF, and the dividing line between the two directions of bone growth was recognized (Fig. 5). For 23 patients, initial bone growth began at the section of the lateral pterygoid muscle and was separated from

the neocondyle in the 1-month postoperative CT scans. As time passed, the volume of bone growth from the lateral pterygoid muscle increased; thus, reattachment of the lateral pterygoid muscle increased and the lateral pterygoid muscle was finally connected with the neocondyle after osteogenesis until the time at which the neocondyle was stable (the time between the initial neocondyle shape and the stable neocondyle shape), which was equal to neocondyle bone growth in the DLPT. The average time at which the condyle was stable following neocondyle bone growth was 5.6 months postoperatively.

## Discussion

A previous study performed at Peking University School and Hospital of Stomatology demonstrated that neocondyle repositioning had two different movement patterns: a move towards the glenoid fossa and a move anteriorly and medially, which was associated with neocondyle bone growth<sup>4</sup>. This study found that neocondyle bone growth after FFF had two different directions, including the direction of lateral pterygoid traction (DLPT) and the direction towards the glenoid fossa (DGF), which could be used

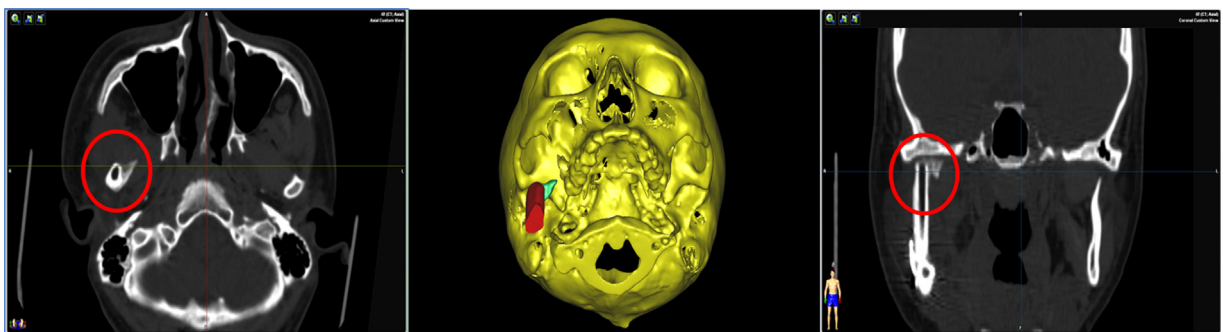


Fig. 3. The red circle shows neocondyle bone growth in the direction of lateral pterygoid traction (DLPT). Three-dimensional models of neocondyle bone growth in the DLPT were created.

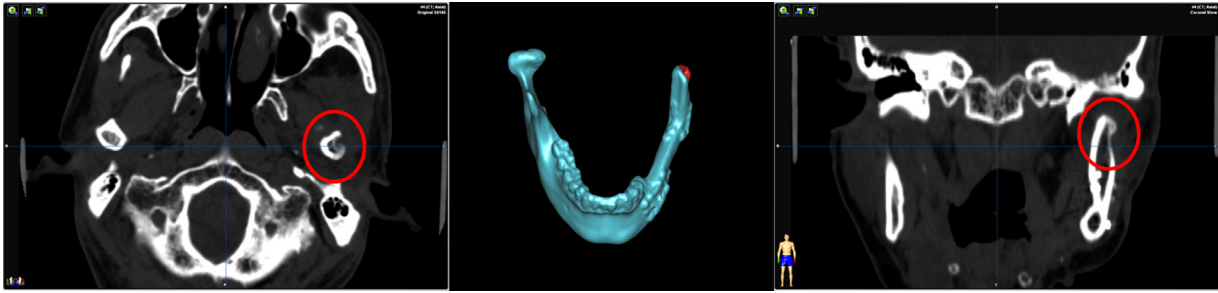


Fig. 4. The red circle shows neocondyle bone growth in the direction of the glenoid fossa (DGF). Three-dimensional models of neocondyle bone growth in the DGF were created.

Table 2. Comparison of new bone formation in the direction of lateral pterygoid traction (DLPT) and in the direction of the glenoid fossa (DGF).

| Group | Number | Average volume, cm <sup>3</sup> | P-value |
|-------|--------|---------------------------------|---------|
| DLPT  | 23     | 0.183 ± 0.167                   | 0.004   |
| DGF   | 17     | 0.446 ± 0.371                   |         |

Table 3. Comparison of new bone formation (cm<sup>3</sup>) between patients aged <18 years and patients aged >18 years.

|               | Neocondyle bone growth | DLPT          | DGF           |
|---------------|------------------------|---------------|---------------|
| Age <18 years | 0.746 ± 0.346          | 0.292 ± 0.197 | 0.681 ± 0.407 |
| Age >18 years | 0.219 ± 0.191          | 0.107 ± 0.073 | 0.237 ± 0.159 |
| P-value       | <0.001                 | 0.001         | <0.001        |

DLPT, new bone formed in the direction of lateral pterygoid traction; DGF, new bone formed in the direction of the glenoid fossa. Mean ± standard deviation values.

to explain the two different movement patterns of the neocondyle. Neocondyle bone growth towards the DGF could guide the neocondyle move towards the temporomandibular fossa. In the present study, CT showed that neocondyle bone growth occurred in two directions, including the DLPT and the DGF. Bone growth in the DLPT began at the section of the lateral pterygoid muscle and was separated from the neocondyle in the 1-

month postoperative CT scans. As time passed, the new bone volume from the lateral pterygoid muscle increased so substantially that reattachment of the lateral pterygoid muscle perhaps occurred and osteogenesis of the lateral pterygoid muscle connected with the neocondyle. Thus, we think that the neocondyle bone growth in the DLPT resulted from ‘distraction osteogenesis’ of the lateral pterygoid muscle.

Many studies have verified that new bone overgrowth is caused by distraction osteogenesis of the lateral pterygoid muscle during the healing of sagittal fractures of the mandibular condyle and after disc and glenoid fossa damage, which together eventually lead to traumatic TMJ bony ankylosis<sup>8,9</sup>. In the previous study at the authors’ institution it was found that the neocondyle could move anteriorly and medially<sup>4</sup>. We know that the inferior head of the lateral pterygoid muscle inserts into the pterygoid fovea under the condylar process of the mandible. Distraction osteogenesis of the lateral pterygoid muscle was anterior and medial, which could explain the direction of neocondyle movement. The role of the lateral pterygoid muscle could potentially be to form bone growth in the DLPT to stabilize the position of the shifting neocondyle.

The lateral pterygoid muscle is an important factor in the development of traumatic TMJ bony ankylosis. In animal experiments, Deng et al. found that blockade of lateral pterygoid muscle function prevented the development of traumatic TMJ bony ankylosis, while maintaining the function of this muscle

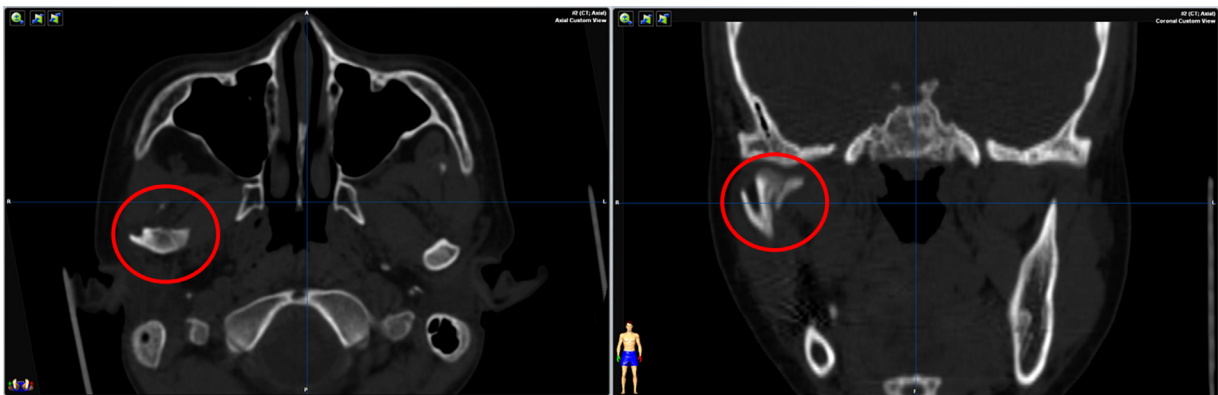


Fig. 5. Bone growth in the direction of lateral pterygoid traction was connected with bone growth in the direction of the glenoid fossa, and the dividing line between these two directions of bone growth was recognized.



successfully established an animal model with traumatic TMJ bony ankylosis<sup>8</sup>. Some studies have demonstrated that the main direction of new trabecular bone in new bone segments is consistent with the DLPT<sup>8,10,11</sup>. Other studies have shown considerable new bone overgrowth in patients with maintained lateral pterygoid muscle function, but no TMJ bony ankylosis was observed; TMJ bony ankylosis was also not observed in the absence of damage to the glenoid fossa. Thus, these authors demonstrated that traction from the lateral pterygoid muscle results in overgrowth of new bone between the fragment and the lateral stump of the condyle; however, it does not result in TMJ bony ankylosis<sup>9,12</sup>. Distraction osteogenesis of the lateral pterygoid muscle during healing leads to bony overgrowth between the fragment and the lateral stump of the condyle.

The main reason for traumatic ankylosis of the TMJ is a bone healing disorder, which is affected by multiple factors. Many studies have confirmed that the development of traumatic TMJ bony ankylosis can occur after post-traumatic bleeding, condylar damage, articular disc rupture/displacement, glenoid fossa damage, or bone grafting in the joint space and lateral pterygoid muscle<sup>13–16</sup>. In the present study, patients who had undergone mandibulectomy for benign or malignant tumours and mandibular reconstruction with FFF had similar conditions, including postoperative bleeding, bone grafting in the joint space, and preservation of the lateral pterygoid muscle. Similarly, new bone around the neocondyle was observed, but no TMJ ankylosis developed. The average volume of bone growth in the DLPT was  $0.183 \pm 0.167 \text{ cm}^3$ . The distance between bone growth in the DLPT and pterygoid process was too great to form a bony bridge.

Neocondyle bone growth was found to be significantly associated with age in this study. The average volumes of new neocondyle bone growth, bone growth in the DLPT, and bone growth in the DGF were significantly greater in patients aged <18 years compared with patients aged >18 years. For patients aged <18 years, the growth potential of the lateral pterygoid muscle and neocondyle was greater, which led to more precise placement of the neocondyle and better neocondyle architecture and function.

The average time at which the condyle was stable following neocondyle bone growth was 5.6 months postopera-

tively. Neocondyle bone growth in the DLPT and DGF was separated from the glenoid fossa by the TMJ disc, which resulted in no persistent postoperative trismus or postoperative temporofibular ankylosis. Bone growth in the DGF remodelled the neocondyle as the normal contour of the condyle, which helped to facilitate the architecture and function of the TMJ.

In conclusion, with preservation of the articular disc, neocondyle bone growth after FFF reconstruction does not develop into temporofibular ankylosis. This bone growth was found to occur in two different directions: in the direction of lateral pterygoid traction and in the direction towards the glenoid fossa. Osteogenesis of the lateral pterygoid muscle affects neocondyle growth in the direction of lateral pterygoid traction. Neocondyle bone growth is more marked in paediatric patients compared with adults.

#### Funding

This work was supported by the National Key Research and Development Project (No. 2019YFF0302400) and the Key Research and Development Program of Ningxia Hui Autonomous Region (No. 2018BEG02012).

#### Competing interests

None of the authors have any financial interests in any of the products, devices, or drugs mentioned in this manuscript.

#### Ethical approval

Ethical approval was obtained from Peking University School and Hospital of Stomatology Biomedical Institutional Review Board (PKUS-SIRB-202055073).

#### Patient consent

Not required.

#### References

- Hidalgo DA. Fibula free flap: a new method of mandible reconstruction. *Plast Reconstr Surg* 1989;**84**:71–9.
- Cordeiro PG, Disa JJ, Hidalgo DA, Hu QY. Reconstruction of the mandible with osseous free flaps: a 10-year experience with 150 consecutive patients. *Plast Reconstr Surg* 1999;**104**:1314–20. <http://dx.doi.org/10.1097/00006534-199910000-00011>.

- sb:contribution>Thankappan K, Trivedi NP, Subash P, Pullara SK, Peter S, Kuriakose MA, Iyer S. Three-dimensional computed tomography-based contouring of a free fibular bone graft for mandibular reconstruction. *J Oral Maxillofac Surg* 2008;**66**:2185–92. <http://dx.doi.org/10.1016/j.joms.2008.01.035>.
- Yu Y, Zhang WB, Liu XJ, Guo CB, Yu GY, Peng X. Regeneration of the neocondyle following fibular free flap reconstruction of the mandibular condyle. *J Oral Maxillofac Surg* 2020;**78**:479–87. <http://dx.doi.org/10.1016/j.joms.2019.11.009>.
- Z-Hye L, Tomer A, Casian M, Patel AA, Hirsch DL, Levine JP. Optimizing functional outcomes in mandibular condyle reconstruction with the free fibula flap using computer-aided design and manufacturing technology. *J Oral Maxillofac Surg* 2018;**76**:1098–106. <http://dx.doi.org/10.1016/j.joms.2017.11.008>.
- González-García R, Naval-Gías L, Rodríguez-Campo FJ, Martínez-Chacón JL, Usandizaga JL. Vascularized fibular flap for reconstruction of the condyle after mandibular ablation. *J Oral Maxillofac Surg* 2008;**66**:1133–7. <http://dx.doi.org/10.1016/j.joms.2007.06.680>.
- Wax MK, Winslow CP, Hansen J, MacKenzie D, Cohen J, Andersen P, Albert T. A retrospective analysis of temporomandibular joint reconstruction with free fibula microvascular flap. *Laryngoscope* 2000;**110**:977–81. <http://dx.doi.org/10.1097/00005537-200006000-00018>.
- Deng TG, Liu CK, Liu P, Zhang LL, Wu LG, Zhou HZ, Ding YX, Hu KJ. Influence of the lateral pterygoid muscle on traumatic temporomandibular joint bony ankylosis. *BMC Oral Health* 2016;**16**:62. <http://dx.doi.org/10.1186/s12903-016-0220-1>.
- Wu D, Yang XJ, Cheng P, Deng TG, Jiang X, Liu P, Liu CK, Meng FW, Hu KJ. The lateral pterygoid muscle affects reconstruction of the condyle in the sagittal fracture healing process: a histological study. *Int J Oral Maxillofac Surg* 2015;**44**:1010–5. <http://dx.doi.org/10.1016/j.ijom.2015.02.004>.
- Sinclair KD, Farnsworth RW, Pham TX, Knight AN, Bloebaum RD, Skedros JG. The artiodactyl calcaneus as a potential ‘control bone’ cautions against simple interpretations of trabecular bone adaptation in the anthropoid femoral neck. *J Hum Evol* 2013;**64**:366–79. <http://dx.doi.org/10.1016/j.jhevol.2013.01.003>.
- Milovanovic P, Djonic D, Marshall PR, Hahn M, Nikolic S, Zivkovic V, Amling M, Djuric M. Microstructural basis for particular vulnerability of the superolateral neck trabecular bone in the postmenopausal women with hip fractures. *Bone* 2012;**50**:63–8. <http://dx.doi.org/10.1016/j.bone.2011.09.044>.
- Liu CK, Liu P, Meng FW, Deng BL, Xue Y, Mao TQ, Hu KJ. The role of the lateral

- pterygoid muscle in the sagittal fracture of mandibular condyle (SFMC) healing process. *Br J Oral Maxillofac Surg* 2012;**50**:356–60. <http://dx.doi.org/10.1016/j.bjoms.2011.05.015>.
13. Long X. The relationship between temporomandibular joint ankylosis and condylar fractures. *Chin J Dent Res* 2012;**15**:17–20.
14. He DM, Yang C, Chen MJ, Zhang XH, Qiu YT, Yang XJ, Li LZ, Fang B. Traumatic temporomandibular joint ankylosis: our classification and treatment experience. *J Oral Maxillofac Surg* 2011;**69**:1600–7. <http://dx.doi.org/10.1016/j.joms.2010.07.070>.
15. Arakeri G, Kusanale A, Zaki GA, Brennan PA. Pathogenesis of post-traumatic ankylosis of the temporomandibular joint: a critical review. *Br J Oral Maxillofac Surg* 2012;**50**:8–12. <http://dx.doi.org/10.1016/j.bjoms.2010.09.012>.
16. Yan YB, Liang SX, Shen J, Zhang JC, Zhang Y. Current concepts in the pathogenesis of traumatic temporomandibular joint ankylosis. *Head Face Med* 2014;**4**:35. <http://dx.doi.org/10.1186/1746-160X-10-35>.

Address:  
Xin Peng  
Department of Oral and Maxillofacial  
Surgery  
Peking University School and Hospital of  
Stomatology  
22# Zhongguancun South Avenue  
Beijing 100081  
China  
Tel.: +86 10 82195210;  
Fax: +86 10 62173402  
E-mail: [pxpengxin@263.net](mailto:pxpengxin@263.net)