



# Postoperative outcomes of adult patients with sagittal fractures of mandibular condyle: Quantitative evaluation and retrospective factor analysis

Xiuling Huang<sup>a, b</sup>, Juanhong Meng<sup>b, c</sup>, Jingang An<sup>b, c, \*</sup>, Yi Zhang<sup>b, c</sup>

<sup>a</sup> Third Clinical Division, Peking University School and Hospital of Stomatology, Beijing, China

<sup>b</sup> National Engineering Laboratory for Digital and Material Technology of Stomatology, Beijing Key Laboratory of Digital Stomatology, Beijing, China

<sup>c</sup> Department of Oral and Maxillofacial Surgery, Peking University School and Hospital of Stomatology, Beijing, China

## ARTICLE INFO

### Article history:

Paper received 31 May 2019

Accepted 14 February 2020

Available online 22 February 2020

### Keywords:

Sagittal fracture of mandibular condyle

Surgical treatment

Temporomandibular joint

Quantitative evaluation

Factor analysis

## ABSTRACT

**Purpose:** We attempted to adopt quantitative methods to precisely evaluate the surgical effect of sagittal fractures of mandibular condyle (SFMCs) and aimed to determine differences in postoperative results between different groups of patients.

**Materials and methods:** Postoperative data of patients with SFMC were collected and quantitative evaluations of subjective, clinical and imaging results were performed. SPSS software was used to analyze the data, and certain factors (gender, age, unilateral or bilateral SFMCs, injury time) were analyzed by univariate analysis.

**Results:** Forty-four postoperative patients were included with an average follow-up of 15.7 months. Averages of resting pain, moving pain, and chewing pain were all <10. Averages of maximum mouth opening, protrusion, and ipsilateral excursive movement were 42.20, 4.80, and 5.98 mm, respectively. Moreover, 85.71% of condylar healing and remodeling was good, and average condylar absorption was 1.52 mm. Early-operated patients (injury time ≤2 weeks) exhibited greater ipsilateral excursive movement, higher condylar index, and lesser condylar absorption than late-operated patients (injury time >2 weeks). Patients with unilateral SFMC showed greater protrusive movement and higher condylar index than those with bilateral SFMCs.

**Conclusion:** Most patients with SFMCs could obtain good subjective, clinical and imaging results by appropriate surgical treatment. Early surgery could improve postoperative outcomes.

© 2020 Published by Elsevier Ltd on behalf of European Association for Cranio-Maxillo-Facial Surgery.

## 1. Introduction

As a special type of condylar fracture, sagittal fracture of mandibular condyle (SFMC) viz. condylar head or diacapitular fracture definitely involves the complicated and sophisticated temporomandibular joint (TMJ). In the past, clinicians usually chose conservative treatment to avoid secondary damage to the TMJ. Recently, several studies (Hlawitschka et al., 2005; Neff et al., 1999; Rutges et al., 2007) have proven that closed treatment probably causes condylar deformation, which leads to TMJ dysfunction such as malocclusion, pain, click or crepitation, and restricted jaw

movement. Over the past decade, with the rapid development of medical material and surgical technique, clinicians have become more positive about surgical treatment for SFMC.

Surgical indications recently have reached a preliminary consensus: (i) SFMCs in which the stump of the ramus dislocates laterally out of the glenoid fossa; (ii) SFMCs with a shortening of the ascending ramus (Duan et al., 2011; He et al., 2009). Numerous studies (Benech et al., 2011; Hlawitschka et al., 2005; Kolk et al., 2015) have demonstrated that good facial contour, mandibular movement, and occlusion could be restored through surgery in most patients, with a low incidence of surgical complications. Moreover, several studies (Berner et al., 2015; Hlawitschka et al., 2005; Neff et al., 1999) have proven that surgical treatment could achieve better results than conservative treatment for SFMCs. However, most previous studies have been limited to general

\* Corresponding author. Department of Oral and Maxillofacial Surgery, Peking University School and Hospital of Stomatology, 22 Zhongguancun Nandajie, Haidian District, Beijing, 100081, PR China.

E-mail address: [anjingang@126.com](mailto:anjingang@126.com) (J. An).

clinical and imaging examinations, failing to use more quantitative evaluation methods to assess postoperative results more precisely.

Although most patients achieved satisfying results after surgery, a small number of patients were likely to face postoperative complications such as TMJ pain, click or crepitation, limited jaw movement, condylar absorption, and even TMJ ankylosis. We wondered whether certain factors would affect postoperative results, including gender, age, unilateral or bilateral SFMCs, and injury time.

Our research was aimed to use multi-dimensional quantitative evaluation methods to perform a detailed and precise assessment of postoperative results in SFMC patients, and on the basis of this assessment, we attempted to determine the differences in treatment results between different groups of patients.

## 2. Materials and methods

### 2.1. Patients collection

Patients had been collected at the Oral and Maxillofacial Trauma Centre, School of Stomatology, Peking University from 2014 to 2016. All were displaced SFMCs with a shortened ramus or with the stump of the ramus dislocated out of the glenoid fossa. Inclusion criteria: i. Patients who underwent surgical treatment of SFMCs in our hospital; ii. Patient age was no less than 16 years at the time of injury; iii. Time from injury to operation was no more than 30 days; iv. Follow-up time was at least six months. Exclusion criteria: i. Patients who had secondary surgery and patients with pre-traumatic TMJ diseases or symptoms; ii. Patients with rheumatism or rheumatoid arthritis or taking drugs that affect bone metabolism; iii. Patients with poor compliance.

### 2.2. Treatment

The interval time from injury to operation was between 2 and 30 days. The delayed surgery of some patients was usually caused by problems reaching a hospital or accompanying injuries that prevented early surgery. Surgery was performed by three experienced surgeons (Jingang An, Yi Zhang and Yang He), and the joints were accessed via the modified auricular approach. The preferred fixation method was using one or two titanium screws ( $\Phi$  2.0 mm, length: 16 or 18 mm, Johnson & Johnson, USA). Steel wire could also be used when some comminuted fractures could not be fixed with screws (Fig. 1). After SFMCs were fixed, we reduced and fixed the displaced disc and repaired the capsule. All concomitant fractures of the mandible were treated according to standard principles of functionally stable osteosynthesis. Elastic traction was applied during the early postoperative period (3–5 days). All patients were instructed to follow a liquid diet for 1 week, semi-liquid food for 1 week, and a strict soft diet for another 2 weeks. Patients began intensive physiotherapy after the first postoperative week. The follow-up duration ranged 6–38 (mean: 15.7) months.

### 2.3. Quantitative evaluations

Subjective evaluation included visual analogue scale (VAS, from 0 to 100) of TMJ pain and chewing ability as well as Mandibular Function Impairment Questionnaire (MFIQ) (Stegenga et al., 1993).

Clinical examinations involved inspection, palpation, and auscultation of the TMJ. Lateral deviation of  $>2$  mm in mouth opening, the range of the maximum mouth opening (MMO), protrusion and laterotrusion, as well as occlusal disturbances were recorded. The aforementioned mandibular movements were measured by the vertical or horizontal distance between the upper and lower incisive points. Clinical findings were summarized by

applying the dysfunction index (DI) according to Helkimo (1974), i.e., mandibular mobility, TMJ function, masticatory muscle pain, TMJ pain, and pain precipitated by movement.

Changes in form and position of the condyle were assessed using cone-beam computed tomography (CBCT). Condylar absorption was calculated: it was equal to immediate postoperative condylar height minus long-term postoperative condylar height. The height of condyle was measured using a published method in the literature (Goran et al., 2015) based on the CBCT images. The measured value is the vertical distance from the highest point of the condyle to the tangent of the lowest point of the sigmoid notch in the direction of its central axis. Immediate postoperative CBCT was recorded 3–5 days after surgery, and the long-term postoperative condylar height was measured on the CBCT images recorded 6 months after surgery. Besides, we introduced condylar index based on Ho's classification (Ho et al., 2015) to quantitatively evaluate the morphology of the condylar articular surface (Fig. 2). These two radiological parameters were measured twice by two separate examiners (blind method). The minimum measurement interval was 1 week. The consistency test found that the intra-rater and inter-rater reliability reached above 0.80 (see Appendix Table 1 for details).

Therefore, multidimensional quantitative results were available: i. subjective evaluation: pain VAS (including resting pain, movement pain and chewing pain), chewing ability VAS, and MFIQ score; ii clinical evaluation: the range of MMO, protrusion and laterotrusion, and DI; iii radiological evaluation: condyle absorption as well as condylar index.

### 2.4. Statistical analysis

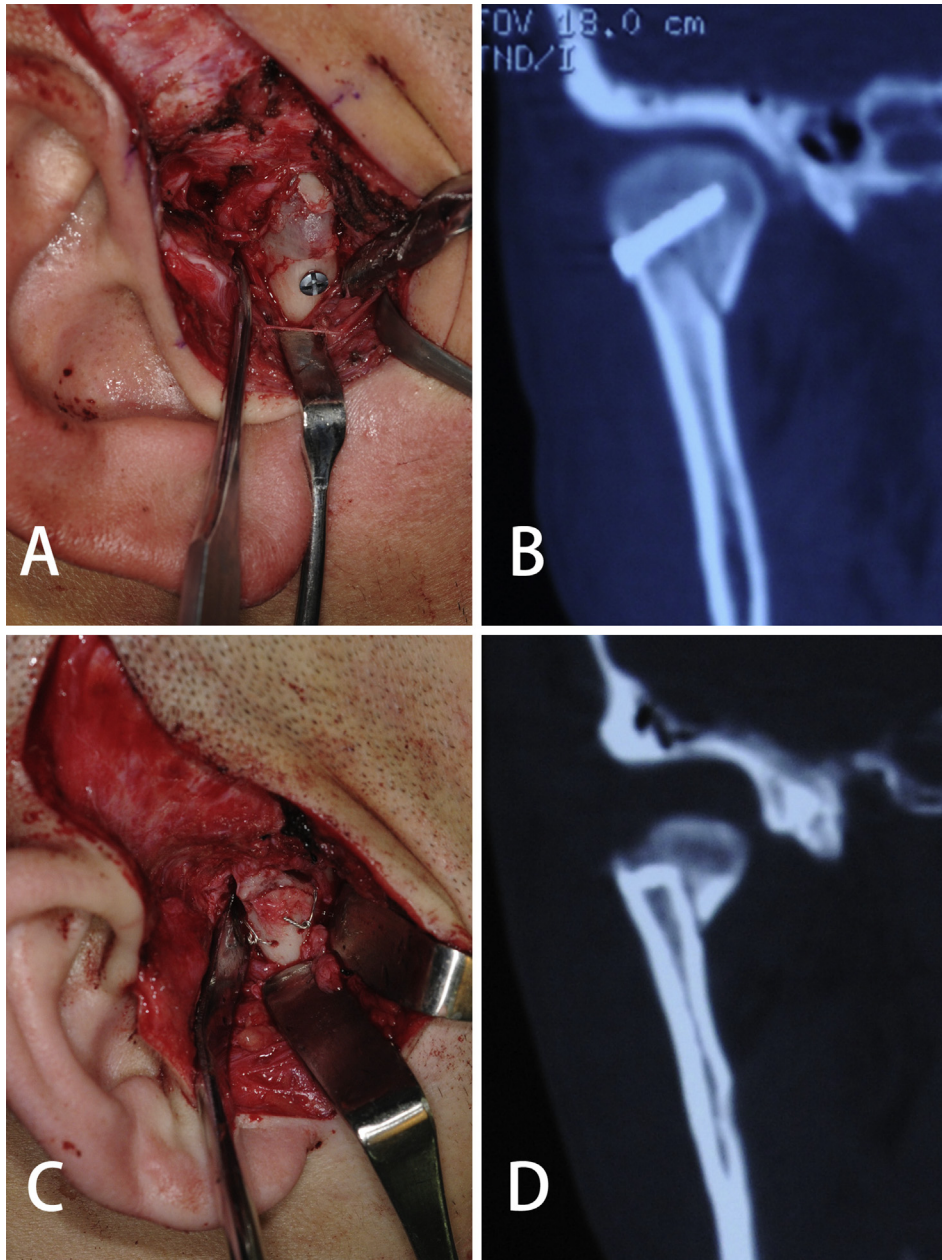
Shapiro–Wilk test was used to test the normality of numerical variables. The numerical variables that conformed to normal distribution were described by mean and standard deviation, and the differences between two groups were compared using independent sample t test. The numerical variables that did not conform to normal distribution were described by median and interquartile range, and the differences between two groups were compared using the Mann–Whitney U test (the test statistic was Z). All tests were two-sided and the level of significance was set at 5% ( $P < 0.05$ ). All statistical analyses were performed by a statistician using the Statistical Package for Social Sciences (SPSS), version 22.0 for Windows (SPSS Inc., Chicago, IL, USA).

## 3. Results

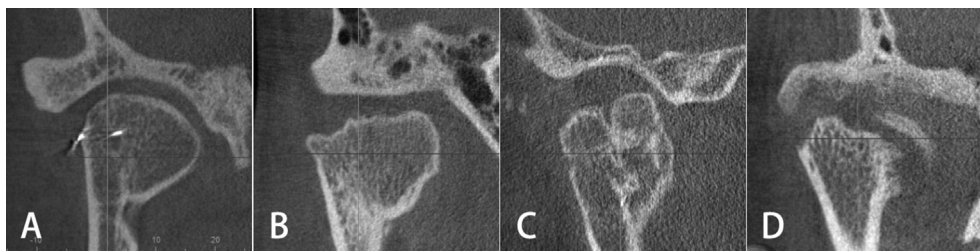
A total of 44 patients (30 males and 14 females, mean age: 33 years, range: 16–63 years) with 64 condylar sagittal fractures (24 unilateral and 20 bilateral) were treated by surgery (Table 1). According to the classification proposed by He (He et al., 2009) based on the position of the fracture line, there were 47 sides of type A fracture, 12 sides of type B, 0 sides of type C, and 5 sides of type M fracture. According to Duan's classification (Duan et al., 2011) based on fracture displacement, there were 0 fractures of V-shaped type, 59 sides of displacement type and 5 sides of dislocation type.

Fifty-eight sides of SFMCs were fixed with screws and six sides fixed with wire. Postoperative CT showed that all 64 fractures were well aligned, yet the relative positions of the condyles to the glenoid fossa were slightly different. Among them, 54 condyles were reduced to the center of the glenoid fossa, 7 condyles were slightly lateral to the center of the fossa, while 3 condyles were too high and almost in contact with the temporal bone.

Follow-up results showed that all the patients had normal facial contour without any mandibular deformity. Except two patients who developed a slight open bite of anterior teeth, 42



**Fig. 1.** Fixation of the sagittal fracture of mandibular condyle. A, B. Intraoperative picture of the miniscrew fixation and immediate CT coronal image. C, D. Intraoperative picture of wire fixation and immediate CT coronal image.



**Fig. 2.** Semi-quantitative evaluation method of condylar index. A. Score four, a normal condylar structure without any signs of change. B. Score three, slight changes and remodeling consisting of an irregular condylar surface. C. Score two, moderate changes and remodeling consisting of flattening of the condyle. D. Score one, signs of osteoarthritis with marked irregularity of the condylar surface and total or partial resorption of the condyle.

**Table 1**  
Patient information.

No.	Gender	Age	To	SFMC	Fixation Method	Follow-up Time
1	M	28	8d	Unilateral	R: screw	38m
2	M	33	6d	Bilateral	R: screw, L: screw	35m
3	F	25	6d	Unilateral	L: screw	31m
4	M	52	30d	Bilateral	R: screw, L: wire	4m
5	M	23	7d	Unilateral	L: screw	31m
6	M	16	5d	Bilateral	R: screw, L: screw	7m
7	F	52	4d	Bilateral	R: screw, L: screw	7m
8	M	34	21d	Bilateral	R: screw, L: screw	7m
9	M	28	4d	Bilateral	R: screw, L: screw	33m
10	M	37	18d	Unilateral	R: screw	13m
11	M	26	4d	Unilateral	R: screw	21m
12	M	55	18d	Bilateral	R: screw, L: screw	20m
13	M	49	15d	Bilateral	R: screw, L: screw	7m
14	F	63	5d	Bilateral	R: screw, L: screw	33m
15	M	21	19d	Unilateral	R: screw	13m
16	F	26	8d	Unilateral	L: screw	18m
17	M	34	7d	Bilateral	R: wire, L: screw	25m
18	F	29	7d	Unilateral	R: screw	10m
19	F	42	13d	Bilateral	R: screw, L: screw	36m
20	F	17	20d	Unilateral	R: screw	9m
21	M	36	6d	Bilateral	R: screw, L: screw	13m
22	M	33	12d	Unilateral	L: screw	10m
23	F	27	8d	Unilateral	R: screw	6m
24	M	27	20d	Unilateral	L: screw	15m
25	M	34	30d	Bilateral	R: screw, L: screw	22m
26	M	37	18d	Unilateral	R: screw	13m
27	M	53	16d	Bilateral	R: screw, L: wire	7m
28	M	21	8d	Unilateral	L: screw	30m
29	F	34	7d	Unilateral	R: screw	6m
30	M	21	7d	Unilateral	R: screw	12m
31	F	17	9d	Unilateral	L: screw	9m
32	M	30	3d	Unilateral	L: screw	6m
33	M	28	30d	Bilateral	R: screw, L: wire	19m
34	F	16	5d	Unilateral	R: screw	11m
35	M	55	2d	Bilateral	R: screw, L: screw	17m
36	F	25	21d	Unilateral	R: screw	6m
37	M	31	14d	Bilateral	R: screw, L: screw	7m
38	M	46	20d	Unilateral	R: screw	23m
39	M	16	9d	Unilateral	L: screw	6m
40	F	24	7d	Bilateral	R: wire, L: wire	7m
41	M	35	12d	Unilateral	L: screw	11m
42	M	44	9d	Bilateral	R: screw, L: screw	17m
43	F	33	9d	Bilateral	R: screw, L: screw	12m
44	M	51	7d	Unilateral	R: screw	6m

Abbreviations: To, time from injury to operation; SFMC, sagittal fracture of mandibular condyle; M, male; F, female.

patients had restored good occlusion. Mean values of VAS of resting pain, movement pain, and chewing pain were 3.80, 5.48, and 5.57 respectively, and 97.73% of patients had no or mild pain of these three (VAS <30). The average VAS of chewing ability was 80.35, and 83.72% of patients had good chewing ability (VAS ≥70). A total of 40 MFIQs were received with an average score of 6.00, and 97.50% of patients had no or mild level of mandibular impairment. Averages of maximum mouth opening, protrusive movement and ipsilateral excursive movement were 42.20, 4.80 and 5.98 mm, respectively. The average Helkimo clinical dysfunction score was 3.05, with 75% of patients having a DI of no more than one, implying that they had no or only mild TMJ symptoms. The mean condylar index of all fractures was 3.10, and 85.71% of condyles were well remodeled (condylar index ≥3). The average condylar absorption was 1.52 mm.

Among the 44 patients, one patient (2 sides) developed fibrous ankylosis of TMJ, and 8 patients (11 sides) had abnormal condylar remodeling (condylar index ≤2) accompanied by obvious symptoms such as joint pain, crepitation, and dysfunction. Twelve patients (13 sides) exhibited good condylar remodeling (condylar index ≥3), while clinical examination revealed certain mild symptoms such as joint tenderness, click, or limited jaw movement.

The remaining 23 patients (52.27%) had normal condylar remodeling, and no abnormality was noted in clinical examination.

The aforementioned quantitative results were compared in order to identify any differences in surgical effect between different groups (Table 2). The chewing ability VAS of female patients was better than that of male patients (90 vs. 80,  $P = 0.011$ ), and no significant difference was observed in other results. Similarly, except chewing ability VAS (90 vs. 80,  $P = 0.004$ ), no significant difference was observed between the young (age ≤25 years) and aged (age >25 years) groups. Certain results of patients with unilateral SFMCs were better than those of patients with bilateral SFMCs: patients with unilateral fractures had slightly more protrusive movement (5.00 mm vs. 4.25 mm,  $P = 0.023$ ) and higher condylar index (4 vs. 3,  $P = 0.001$ ) than those with bilateral fractures. Differences in postoperative outcomes between the early-operated group (injury time ≤14 days) and late-operated group (injury time >14 days) were greater: early-operated patients showed greater ipsilateral excursive movement (6.50 vs. 5.50 mm,  $P = 0.030$ ) and slightly higher condylar index (3 vs. 3,  $Z = -2.756$ ,  $P = 0.006$ ) than did late-operated patients, and their condylar absorption was less than that of late-operated patients (0.66 vs. 1.69 mm,  $P = 0.013$ ).

#### 4. Discussion

SFMCs cause not only hard tissue injury but also soft tissue injuries such as disc displacement along with the fractured fragment, tears in the retrodiscal tissue and capsule, and joint effusion. A magnetic resonance imaging (MRI) study by Yu (Yu et al., 2013) reported disc displacement in 78.9%, tears of the retrodiscal tissue in 84.2%, and tears of the capsule in 47.3% of patients with SFMCs. Another MRI follow-up study (Yang et al., 2015) of patients with conservative treatment revealed that disc replacement and retrodiscal tear allowed for contact between the residual condyle and fossa, resulting in osteoarthritic remodeling, fibrillation of the interposed fibrocartilage, and reactive ossification. Therefore, it is recommended to reduce not only the bone but also the soft tissue, including reduction and fixation of the disc and repair of the capsule. Additionally, more attention should be paid to maintaining adhesion of the lateral pterygoid muscle and protecting the condylar articular cartilage in order to avoid secondary injury and to promote TMJ healing.

Quantitative evaluations showed that subjective feelings of patients were generally consistent with clinical examination results. Results revealed that most patients developed few TMJ symptoms and achieved good mandibular function after surgery. Moreover, CBCT could reveal superficial bone changes of the condyle more clearly compared with panoramic radiogram and spiral CT; hence, in the present study, we could use condylar index to semi-quantitatively evaluate postoperative condylar remodeling by CBCT. Results showed that the condyles restored a normal shape and a smooth continuous surface (condylar index = 4) in 33.33% of fractures, the surface of the condyle was mildly irregular and well remodeled (condylar index = 3) in 52.38%, and an abnormality of condylar reconstruction (condylar index ≤2) occurred in the remaining 14.28% of fractures.

Postoperative TMJ functional and imaging results may be related to various factors. The present study explored possible factors such as gender, age, fracture type (unilateral or bilateral), and injury time. Results revealed that injury time had an obvious impact on postoperative results such as laterotrusion, condylar index, and condyle absorption. In addition, fracture type (unilateral or bilateral) could have a certain impact on postoperative results such as protrusion and condylar index. Gender and age made little difference on postoperative results except for chewing ability VAS.

**Table 2**

The comparisons of surgical results between different groups of patients.

	Rest Pain VAS	Movement Pain VAS	Chewing Pain VAS	Chewing Ability VAS	MFIQ Score	MMO	Protrusion	Laterotrusion <sup>a</sup>	DI	Condylar Index <sup>a</sup>	Condyle Absorption <sup>a</sup>
Total	0 (0)	0 (0)	0 (0)	80 (20)	6 (7.5)	42.00 (7.00)	5.00 (1.50)	6.00 (2.00)	2 (3.75)	3 (1)	−0.78 (1.88)
Male (30)	0 (0)	0 (0)	0 (0)	80 (20)	6 (10)	42.00 (6.50)	5.00 (1.25)	6.00 (2.13)	2 (4)	3 (1)	−0.57 (2.21)
Female (14)	0 (3)	0 (13)	0 (5)	90 (16)	5.5 (7)	40.50 (5.50)	5.00 (1.88)	6.00 (2.00)	2 (1)	3 (1)	−1.04 (1.63)
<i>P</i>	0.263	0.196	0.574	0.011	0.709	0.411	0.949	0.637	0.679	0.843	0.114
A≤25 (12)	0 (0)	0 (8)	0 (8)	90 (19)	3.5 (6)	44.00 (9.25)	5.00 (0.50)	5.75 (2.00)	2 (1)	3.5 (1)	−0.99 (2.57)
A>25 (32)	0 (0)	0 (0)	0 (0)	80 (15)	7 (8)	42.00 (6.00)	5.00 (2.00)	6.00 (2.50)	2 (4)	3 (1)	−0.69 (1.98)
<i>P</i>	0.581	0.505	0.518	0.004	0.119	0.066	0.799	0.516	0.119	0.055	0.314
Unilateral (24)	0 (0)	0 (9)	0 (8)	80 (24)	5 (8)	43.00 (7.50)	5.00 (1.50)	6.00 (2.00)	2 (2)	4 (1)	−0.85 (1.74)
Bilateral (20)	0 (0)	0 (0)	0 (0)	80 (15)	7 (7)	42.00 (6.75)	4.25 (2.75)	6.00 (4.00)	2 (5)	3 (0)	−0.70 (2.49)
<i>P</i>	0.161	0.056	0.213	0.536	0.473	0.201	0.023	0.858	0.139	0.001	0.951
T <sub>0</sub> ≤14d (30)	0 (0)	0 (0)	0 (3)	82 (16)	6.5 (7)	42.00 (9.00)	5.00 (1.13)	6.50 (2.63)	2 (2)	3 (1)	−0.66 (1.37)
T <sub>0</sub> >14d (14)	0 (2)	0 (0)	0 (0)	80 (18)	4 (7)	42.00 (3.50)	5.00 (3.75)	5.50 (4.00)	2 (5)	3 (1)	−1.69 (5.64)
<i>P</i>	0.331	0.626	0.238	0.108	0.441	0.527	0.969	0.030	0.191	0.006	0.013

Note: Indicator values are presented as median (interquartile range) based on Mann–Whitney U test.

Abbreviations: VAS, visual analogue score. MFIQ, mandibular function impairment questionnaire. MMO, maximum mouth opening. DI, Helkimo clinical dysfunction index. A, age. T<sub>0</sub>, time from injury to operation.<sup>a</sup> Calculate only the results of operated sides of mandibular condyle.

With the prolongation of injury time, a series of changes would occur in SFMCs, including blood clot formation, fibrous tissue ingrowth, callus formation, and malunion. These could be accompanied by changes of the disc and capsule, including degeneration, necrosis, and adhesion to surrounding tissues. In a sheep model study (Long et al., 2007), pathological changes including erosion of the articular surface, osteophytes, and outgrowth formation of condylar stumps were observed in the 1-week operation group, and there was a joint space between the temporal bone and the condylar stump; in the 4-week operation group, bone resorption and some new bone formation were observed on both the temporal bone and the condylar stump, and the joint space was filled with fibrous tissue. Therefore, delayed treatment of SFMCs might lead to early malunion as well as abnormal remodeling of the condyle and the temporal bone. Moreover, due to ingrowth of fibrous tissue and osteophyte formation, reduction of fractures and restoration of condyle would become more challenging. Our study proved that early surgery was conducive to normal healing and remodeling of fractures, which would help restore TMJ function, in patients of SFMCs with surgical indications.

It is known that a fractured condyle undergoes reduction in translation even after treatment, and mandibular protrusive movement is primarily completed by translational movement of bilateral condyles. Since patients with bilateral SFMCs had two operated condyles, it was not difficult to understand that their protrusive movement was significantly less than that observed in patients with unilateral SFMCs. Besides, patients with bilateral SFMCs exhibited poorer condylar remodeling than did those with unilateral SFMCs. The reason might be that the former were usually more severely damaged compared with the latter, thus needing more complicated repairs of both soft and hard tissues surrounding TMJ.

Previous studies (Amaratunga, 1988; Proffit et al., 1980) have demonstrated that remodeling and regeneration capabilities of the condyle are age-related. Young individuals have relatively thicker condylar cartilage, which is crucial to condylar remodeling and easily leads to robust growth-related adaptations in case of either protrusive function or condylar fracture and dislocation. In our study, functional and radiological results between young and aged patients had limited significant differences except for chewing ability VAS. The reason might be that less condylar remodeling was needed to complete fracture healing after surgical treatment, which reduced the differences in results between young and aged patients. The chewing ability VAS of young patients was better than

that of aged patients, which was more likely to be associated with better dental conditions and stronger chewing function in younger patients.

## 5. Conclusion

The present study suggested that most patients with SFMCs could obtain good objective, clinical and imaging results through appropriate surgical treatment. When surgery was necessary, early surgery was advocated because it could improve postoperative outcomes.

## Declaration of Competing Interest

There are no acknowledgements or any potential conflicts of interest to report for any of the authors associated with this manuscript.

## Funding

This research did not receive any specific grant from funding agencies in the public, commercial, or not-for-profit sectors.

## Appendix A. Supplementary data

Supplementary data to this article can be found online at <https://doi.org/10.1016/j.jcms.2020.02.011>.

## References

- Amaratunga NA: Mandibular fractures in children—a study of clinical aspects, treatment needs, and complications. *J Oral Maxillofac Surg* 46: 637–640, 1988
- Benech A, Arcuri F, Baragiotta N, Nicolotti M, Bruccoli M: Retroauricular transmeatal approach to manage mandibular condylar head fractures. *J Craniofac Surg* 22: 641–647, 2011
- Berner T, Essig H, Schumann P, Blumer M, Lanzer M, Rucker M, Gander T: Closed versus open treatment of mandibular condylar process fractures: a meta-analysis of retrospective and prospective studies. *J Craniomaxillofac Surg* 43: 1404–1408, 2015
- Duan DH, Zhang Y: A clinical investigation on disc displacement in sagittal fracture of the mandibular condyle and its association with TMJ ankylosis development. *Int J Oral Maxillofac Surg* 40: 134–138, 2011
- Goran M, Lukas M, Raphael P, Malgorzata R, Nina L, Timo PK, Kellenberger CJ: Assessing the length of the mandibular ramus and the condylar process: a comparison of OPG, CBCT, CT, MRI, and lateral cephalometric measurements. *Eur J Orthod* 37(13), 2015
- He D, Yang C, Chen M, Jiang B, Wang B: Intracapsular condylar fracture of the mandible: our classification and open treatment experience. *J Oral Maxillofac Surg* 67: 1672–1679, 2009

- Helkimo M: Studies on function and dysfunction of the masticatory system. II. Index for anamnestic and clinical dysfunction and occlusal state. *Sven Tandlak Tidskr* 67: 101–121, 1974
- Hlawitschka M, Loukota R, Eckelt U: Functional and radiological results of open and closed treatment of intracapsular (diacapitular) condylar fractures of the mandible. *Int J Oral Maxillofac Surg* 34: 597–604, 2005
- Ho SY, Liao HT, Chen CH, Chen YC, Chen YR, Chen CT: The radiographic and functional outcome of bilateral mandibular condylar head fractures: a comparison between open and closed treatment. *Ann Plast Surg* 74(Suppl 2): S93–S98, 2015
- Kolk A, Neff A: Long-term results of ORIF of condylar head fractures of the mandible: a prospective 5-year follow-up study of small-fragment positional-screw osteosynthesis (SFPSO). *J Craniomaxillofac Surg* 43: 452–461, 2015
- Long X, Goss AN: A sheep model of intracapsular condylar fracture. *J Oral Maxillofac Surg* 65: 1102–1108, 2007
- Neff A, Kolk A, Deppe H, Horch HH: [New aspects for indications of surgical management of intra-articular and high temporomandibular dislocation fractures]. *Mund Kiefer Gesichtschir* 3: 24–29, 1999
- Proffit WR, Vig KW, Turvey TA: Early fracture of the mandibular condyles: frequently an unsuspected cause of growth disturbances. *Am J Orthod* 78: 1–24, 1980
- Rutges JP, Kruizinga EH, Rosenberg A, Koole R: Functional results after conservative treatment of fractures of the mandibular condyle. *Br J Oral Maxillofac Surg* 45: 30–34, 2007
- Stegenga B, de Bont LG, de Leeuw R, Boering G: Assessment of mandibular function impairment associated with temporomandibular joint osteoarthritis and internal derangement. *J Orofac Pain* 7: 183–195, 1993
- Yang X, Yao Z, He D, Cai Y, Dong M, Yang C: Does soft tissue injury affect intracapsular condylar fracture healing? *J Oral Maxillofac Surg* 73: 2169–2180, 2015
- Yu YH, Wang MH, Zhang SY, Fang YM, Zhu XH, Pan LL, Yang C: Magnetic resonance imaging assessment of temporomandibular joint soft tissue injuries of intracapsular condylar fracture. *Br J Oral Maxillofac Surg* 51: 133–137, 2013