

# Six cases of central cystadenocarcinoma and review of relevant papers

R. Sun<sup>a</sup>, H.-w. Zhang<sup>b</sup>, W.-b. Zhang<sup>a</sup>, Y. Yu<sup>a</sup>, G.-y. Yu<sup>a</sup>, X. Peng<sup>a,\*</sup>

<sup>a</sup> Department of Oral and Maxillofacial Surgery, Peking University School and Hospital of Stomatology, Beijing, China

<sup>b</sup> Department of Head and Neck Surgery, Tangshan People's Hospital, Tangshan, Hebei, China

Accepted 29 June 2020

Available online 13 July 2020

## Abstract

The present study was a review of cases of central cystadenocarcinoma over the past 29 years and provides clinical, radiological, and pathological information about these rare lesions. Six cases of central cystadenocarcinoma treated between 1991 and 2019 at Peking University Hospital of Stomatology in Beijing, China, were retrospectively analysed. A comprehensive review of clinical records was summarised and the histological diagnosis was revised using the 2017 World Health Organization criteria. The mean age of patients with central cystadenocarcinoma was 63 (range 51–75) years, and the male:female ratio 1:1. The clinical signs included localised swelling, pain, lower lip numbness, and trismus. There were more cases in the mandible than in the maxilla. All lesions were unilocular or multilocular in radiolucent regions with or without clear margins. The preferred treatment of central cystadenocarcinoma was surgical excision with wide margins, and no local recurrence was found during follow-up. Central cystadenocarcinoma often occurred in middle-aged or elderly patients. Because cystadenocarcinoma is somewhat rare, metastatic tumours of the jaw should be considered when diagnosing cystadenocarcinoma.

© 2020 The British Association of Oral and Maxillofacial Surgeons. Published by Elsevier Ltd. All rights reserved.

**Keywords:** central cystadenocarcinoma; intraosseous; salivary gland tumor; mandible

## Introduction

Cystadenocarcinoma of the salivary gland is a rare malignant tumour characterised by predominantly cystic growth that often exhibits intraluminal papillary growth.<sup>1</sup> Cystadenocarcinoma was renamed “papillary cystadenocarcinoma” in the revised World Health Organization (WHO) classification of 1991.<sup>2</sup> Then it was described using the term “cystadenocarcinoma” by Ellis and Auclair’s classification in 1996.<sup>3,4</sup> Cystadenocarcinoma mostly occurs in the major salivary

glands, and the buccal mucosa, lips, and palate are the most commonly involved minor gland sites.<sup>4</sup> In some rare cases, the primary sites of cystadenocarcinoma have been reported to be the mandible or maxilla. Specifically, the mandible has been reported to be the primary site in five previously reported cases,<sup>3,5–8</sup> and the maxilla has been found in only one case.<sup>9</sup>

According to the latest WHO classification of head and neck tumours, cystadenocarcinomas have become diagnoses of exclusion and are part of “adenocarcinomas, not otherwise specified”.<sup>10</sup> However, the biological behaviour of central cystadenocarcinomas of the jaw has not yet been elucidated and long-term follow-up data are lacking. On this occasion, the surgical strategy of cystadenocarcinomas, as well as the application of a postoperative adjuvant treatment, could not reach a consensus. The appropriate extent of mandibulectomy for the balance between quality of life and the survival rate

\* Corresponding author at: Department of Oral and Maxillofacial Surgery, Peking University School and Hospital of Stomatology, 22# Zhongguancun South Avenue, Beijing 100081, China. Tel: +86 010 82195210, Fax: +86 010 82195210.

E-mail address: [pxpengxin@263.net](mailto:pxpengxin@263.net) (X. Peng).

should be considered. To gain further understanding of the characteristics of cystadenocarcinoma, therefore, six cases of central cystadenocarcinoma are presented in this retrospective study.

## Material and methods

### Inclusion and exclusion criteria

Over the past 29 years (1991–2019), patients who were diagnosed with central cystadenocarcinoma and received surgical treatment at our institution were enrolled in our study. The diagnosis criteria for central cystadenocarcinoma include the presence of cortical plates around the tumour, radiographic evidence on computed tomography (CT) of bony destruction, and typical histological findings, which are consistent with cystadenocarcinoma. Cases were excluded if the tumour was an invasive overlying cystadenocarcinoma. Paraffin-embedded tissue underwent haematoxylin and eosin staining and immunohistochemical staining and were diagnosed by a certified pathologist according to the 2017 WHO criteria.<sup>11</sup>

### Data collection

Detailed clinical data, including the demographic information, chief complaint, location of lesion, sign/symptoms, radiological examination, treatment, and follow-up, were retrieved from each patient's medical charts. The available detailed information of these patients was analysed. In addition, the clinical management of each case was summarised, including the use of surgical excision and radiological treatment, among others. Each treatment decision was decided by specific doctors based on experience, and different surgeons did the surgical excisions. Recurrence was evaluated by clinical and radiological examination.

This study followed the Declaration of Helsinki on medical protocol and ethics and the regional Ethics Review Board of the Peking University School and Hospital of Stomatology approved the study. We have obtained the patients' free informed consent to use clinical photographs.

## Results

During the preliminary screening, 12 patients were enrolled according to the inclusion criteria. However, after further screening, six patients, whose radiological examinations were not found or whose lesions were in the minor salivary gland (such as the palate or retromolar region), were excluded. Six patients were therefore enrolled in our study. The gender composition of the enrolled patients was 1:1 (male: female), and the mean age of the patients was 63 (range 51–75) years old. As there is only one case every few years,

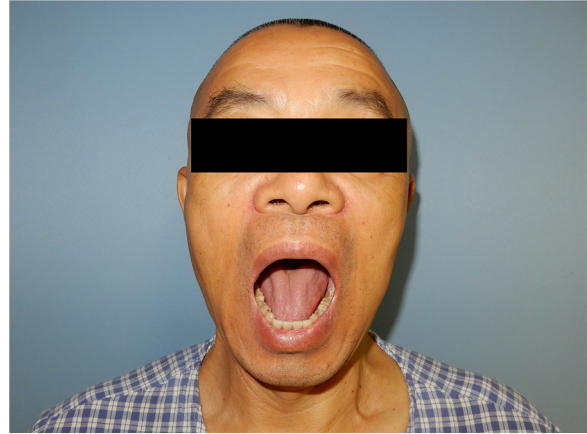

Fig. 1. Patient no. 6: slight swelling was found in the posterior body of the left mandible with no limit to mouth opening.

the follow-up period ranged from 1 month to 144 months, with a mean of 54 months.

All lesions were located in the mandible, in which four were found in the right half, three were in the ramus and posterior body, two were in the ramus, and one was in the angle. Of all the six cases, only one had tooth involvement. However, the tooth was not in the lesion. All patients displayed localised swelling; four patients had pain and two patients felt lower lip numbness. All patients received partial resection of the mandible, four of which were supraomohyoid neck dissections. The defect “mandibular” is classified according to HCL classification.<sup>12</sup>

No local recurrence was found in any of the six cases during the follow-up period. Four patients are still alive, while two patients have been withdrawn because of loss to follow-up as a result of changes in correspondence details. In one patient, a metastasised lymph node was discovered in the Ib region, then metastases were found in the sternum approximately 17 months postoperatively (Table 1).

Patient number 6 was a 64-year-old man who found painless swelling in his left mandible with no limit to mouth opening (Fig. 1). Panoramic radiography showed a multilocular radiolucent tumour with a clear margin in the posterior mandibular body and the anterior of the mandibular ramus (Fig. 2), while contrast-enhanced CT showing a thin cortical bone around the tumour; the inferior alveolar canal was not seen (Supplemental data). The partial mandibulectomy was done from the condyle to the ipsilateral second premolar (Fig. 3), and the defect was reconstructed by a fibular flap (Fig. 4). Histopathological examination of the tumour showed cystic cavities lined with a single layer of cuboidal cells with mild nuclear pleomorphism (Supplemental data). All tumour cells were immunoreactive for CK, CK7, CK8/18, SOX10, and Dog-1, but not for CK20, SMA, P63, P40, TTF-1, TG, PSA, Hep-Par-1, CD10, and RCC. The ratio of ki67 positive immunoreactive cells was approximately 7%–9%. Partial tumour cells were immunoreactive for CK5/6, CK19, S-100, and mammaglobin. Suspicious positive tumour cells were

Table 1  
Clinical information for the six central cystadenocarcinoma patients.

Case No.	Gender	Primary age (years)	Signs/symptoms	Imaging manifestations	Site	Surgical treatment	HCL classification	T	N	M	G	Stage	Follow up	Postoperative treatment	Alive
1	Female	56	Painless swelling	Unilocular, without tidy margin	Left ramus	Partial resection of mandible (from the condylar neck to the ipsilateral first premolar), supraomohyoid neck dissection, reconstructed by fibular flap.	L	1	0	0	1	IA	No local recurrence in 148 months	None	Yes
2	Male	75	Painful swelling, lower lip numbness	Unilocular, without tidy margin	Right angle	Partial resection of mandible (the angle of mandible), supraomohyoid neck dissection, primary closure.	L	1	0	0	1	IA	No local recurrence in 10 months	None	N/A
3	Female	68	Painful swelling, limited mouth opening	Multilocular, without tidy margin	Right ramus and posterior of body	Partial resection of mandible (from the condylar neck to the ipsilateral first premolar), supraomohyoid neck dissection, reconstructed by fibular flap.	L	1	0	0	1	IA	No local recurrence in 40 months	None	N/A
4	Female	51	Painful swelling, teeth loosening	Unilocular, without tidy margin	Right ramus and posterior of body	Partial resection of mandible (from the condylar neck to the ipsilateral first molar), reconstructed by fibular flap.	L	1	0	0	1	IA	No local recurrence in 82 months	None	Yes
5	Male	63	Painful swelling, lower lip numbness	Unilocular, without tidy margin, tooth involved	Right ramus	Partial resection of mandible (from the condylar neck to the ipsilateral second premolar), supraomohyoid neck dissection, reconstructed by fibular flap.	L	1	1	1b	1	IVB	Sternum metastasis in 17 months; no local recurrence in 41 months	Chemotherapy, radiological treatment to sternum	Yes
6	Male	64	Painless swelling	Multilocular, without tidy margin	Left ramus and posterior of body	Partial resection of mandible (from the condylar to the ipsilateral second premolar), reconstructed by fibular flap.	H	1	0	0	1	IA	No local recurrence in 1 month	None	Yes

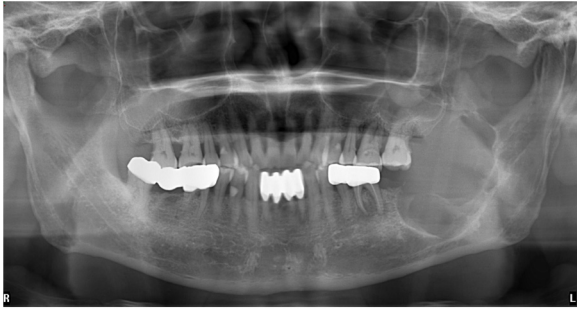

Fig. 2. Panoramic radiograph shows a multilocular radiolucent tumour with clear margins in the posterior mandibular body and the anterior of the mandibular ramus.

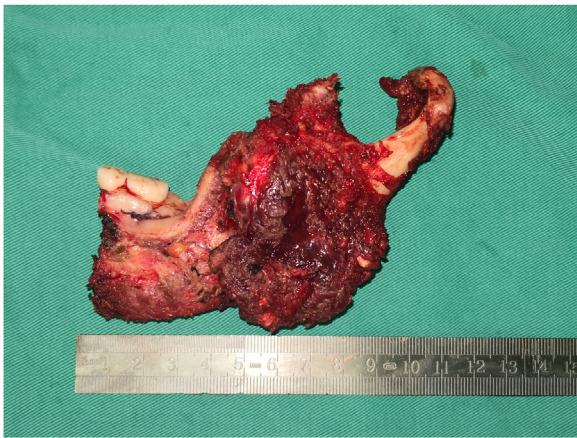

Fig. 3. The specimen of tumour after mandibulectomy.

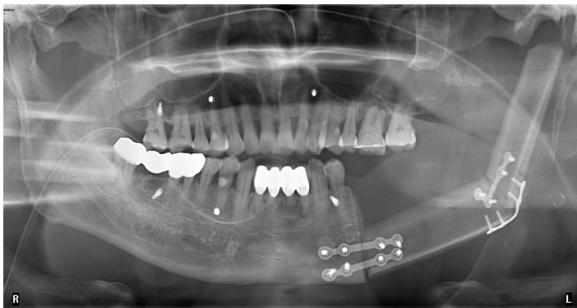


Fig. 4. Panoramic radiograph showing titanium plates fixed to the bone grafts two weeks postoperatively.

immunoreactive for vimentin and human epidermal growth factor-receptor 2 (Her-2).

## Discussion

Cystadenocarcinoma of the salivary gland is a type of low-grade adenocarcinoma, which has also been reported as papillary cystadenocarcinoma, mucus-producing adenopapillary (non-epidermoid) carcinoma, or malignant papillary cystadenoma, in published papers.<sup>4</sup> There has been no sex bias observed in the incidence rate of cystadenocarcinoma

and approximately 65% occur in the major salivary glands. The mean age of cystadenocarcinoma patients is nearly 60 years old.<sup>1</sup> On rare occasions, cystadenocarcinoma arises centrally inside the jaws. Recently, six cases of central cystadenocarcinoma have been reported.<sup>3,5–9</sup>

The pathogenesis of central malignant salivary gland tumours is still disputable and some hypotheses have been proposed, including: 1) ectopic salivary gland tissue that was developmentally entrapped in the jaws; 2) neoplastic transformation of the sinus epithelium; 3) aberrant induction of salivary tissue from the dental lamina epithelium during embryonic development; 4) neoplastic transformation of the epithelial lining of an odontogenic cyst (especially dentigerous cysts); and 5) entrapment of minor salivary glands from chronic osteomyelitis.<sup>5,7,13–15</sup>

Some studies have indicated that impacted teeth or dental cysts have certain associations with the origin of central salivary gland tumours.<sup>6,16</sup> In our study, limited evidence could be found between the impacted tooth and central cystadenocarcinoma. As a rare type of salivary gland carcinoma that occurs in the mandible, the potential of cystadenocarcinoma to be a metastasis to the jaw should be considered, in which the possible primary lesion may have originated from ovary, gastrointestinal tract, or gallbladder. In all six cases in the present study, patients were referred to general hospitals to receive a physical check-up and necessary auxiliary examinations, but no cystadenocarcinoma was found in other parts of the body.

Most of our cases were classified as stage IA, which indicated low-grade biological behaviour of the central cystadenocarcinoma. We observed one stage IVA case with a lesion in the right ramus; this patient had a history of central cystadenocarcinoma of his left mandible, which had previously been resected twice at another hospital. This finding suggests, therefore, that recurrent or multiple primary cases may be of a potentially higher grade. The clinical manifestation of central cystadenocarcinoma in the mandible includes painless or painful swelling, limited mouth opening, lower lip numbness, and teeth loss. When the lesion is mostly located in the ramus or posterior mandible body, limited mouth opening would occur if the tumour destructs the integrity of the cortical bone.

When we examined imaging manifestations of mandibular cases, panoramic imaging showed unilocular or multilocular radiolucency with or without clear margins, and CT showed a thin bone around the expansile mass; the inferior alveolar canal was often involved. In a previous study of 22 cases of central malignant salivary gland tumours, all lesions were shown as radiolucent regions with ill-defined margins,<sup>7</sup> which was consistent with our study. The radiological findings consisted of a unilocular or multilocular, radiolucent mandibular lesion, similar to a benign jaw tumour<sup>17</sup> or jaw metastases.<sup>18</sup>

According to the latest WHO classification of head and neck tumours, the notable modifications in salivary gland tumours include the grouping of rare subtypes of epithelial

Table 2  
Central cystadenocarcinoma information from previous studies.

First author, year, and reference	Gender	Primary age (years)	Signs/symptoms	Imaging manifestations	Site	Surgical treatment	Follow up	Postoperative treatment	Immunohistochemical
Johnston 2006 <sup>3</sup>	Female	73	Bilateral jaw pain	Multilocular, well-corticated	Right mandibular angle	Curettage, marginal mandibulectomy	N/A	N/A	N/A
Cavalcante 2007 <sup>9</sup>	Male	79	Painless swelling	Destruction of cortical bone	Left maxilla	No	N/A	N/A	p53(+)
Li 2008 <sup>7</sup>	Female	56	Swelling	N/A	Mandibular ramus	Hemimandibulectomy	Recurrence in 8 months	N/A	N/A
Takei 2012 <sup>6</sup>	Female	64	Painful swelling	Multilocular, well-defined margin	Right mandibular body	Partial resection of mandible, supraomohyoid neck dissection	No local recurrence or metastasis in 26 months	None	CK7(+), CK34Be12(+), S100(–), vimentin(–), carcinoembryonic(–)
Srivanitchapoom 2014 <sup>5</sup>	Female	65	Painless swelling	Mmultilocular,	Right mandibular ramus	Segmental mandibulectomy, parotidectomy, submandibular gland resection, postoperative radiotherapy	No local recurrence in 1 year	None	CK7(+), CK19(+), CEA(+), CDX-1(–), CK20(–), CA-125(–), TTF(–)
Madathil 2018 <sup>8</sup>	Male	71	Rapid increase in size, swelling	Radiolucent lesion with irregular margin	Right mandibular body	No	N/A	N/A	N/A

carcinoma that share similar pathological and clinical characteristics under adenocarcinoma not otherwise specified, including cystadenocarcinoma, mucinous adenocarcinoma, and intestinal adenocarcinoma.

Since immunohistochemistry is rarely valuable when diagnosing cystadenocarcinoma, and the cells of cystadenocarcinoma co-express cytokeratin's AE1-AE3, CK7, CK14, and the p63 protein,<sup>19</sup> the possible diagnosis strategy is the exclusive method. Cystadenomas can be separated from cystadenocarcinomas because of the lack of stromal invasion and cellular atypia.<sup>20</sup> Low-grade mucoepidermoid carcinoma may also present cystopapillary structures but can be differentiated from cystadenocarcinomas by the presence of mucus-producing cells intermingled with epidermoid cells lining the cysts and by the presence of intermediate cells arranged in solid structures.<sup>21</sup> The papillary-cystic variant of acinic cell carcinoma could be accurately diagnosed based on the presence of microcystic and follicular growth patterns and serous acinar cells with periodic acid Schiff (PAS)-positive zymogen granules in the cytoplasm.<sup>22</sup> In contrast to conventional cystadenocarcinoma, intraductal carcinoma (formerly called low-grade cribriform cystadenocarcinoma) is composed of solid, cribriform, and anastomosing micropapillary intracystic structures.<sup>11</sup> The cells of intraductal carcinoma express cytokeratins CK7, CK8, CK18, and CK19, as well as the S-100 protein. Cystadenocarcinoma tends to be invasive, whereas intraductal carcinoma is usually surrounded by an intact myoepithelial layer.<sup>11</sup>

According to the AJCC Cancer Manual, tumours arising in minor salivary glands are staged according to the anatomical site of origin.<sup>23</sup> For facial bones 'T' is divided into lesions with a maximum dimension of 8 cm or less (T1) and those greater than 8 cm (T2). T3 has been redefined to include only high-grade, discontinuous, tumours, within the same bone. 'N' is divided into lesions with regional lymph node metastases (N1) or without lymph node metastases (N0). Histological grading (G) uses a three-tiered system, including G1 that is considered to be low grade, and G2 and G3 that are grouped together as high grade for biological grading.<sup>24</sup>

In the previous six cases that have been published, two cases did not receive surgical treatment.<sup>8,9</sup> Four mandibular lesions received en bloc resection, including marginal mandibulectomy, hemimandibulectomy, partial resection of the mandible, and segmental mandibulectomy, and only one case had supraomohyoid neck dissection. However, no information was given on lymph node metastases (Table 2). All six cases in our study had partial mandibulectomy, four of whom also had supraomohyoid neck dissection. Lymph node metastases were found in only one case.

In all the cases that had surgical treatment in the previous studies and our study, there were a total of 10 mandibular cases.<sup>3,5–8</sup> Seven of the patients were female, aged 51 to 75 years old at the time of primary surgery. Swelling was the most common symptom (9/10), followed by local pain (6/10), paraesthesia of the lip (2/10), and trismus (1/10). Local recurrence and regional lymph node metastases were

rare (1/10). In a previous study of 57 cases of salivary gland cystadenocarcinoma, the rates of local recurrence and the occurrence of regional lymph node metastasis were 7.5% and 10%, respectively; however, no central cystadenocarcinoma was included.<sup>1</sup>

## Conclusion

Central cystadenocarcinoma of the mandible is a rare subtype of low-grade adenocarcinoma NOS. Because the incidence is rather low, the prognosis of central cystadenocarcinoma remains unclear. The preferred treatment of the tumour is surgical excision with wide margins. The postoperative adjuvant treatment should be applied according to the stage of the tumour. Considering that cystadenocarcinoma is rare, metastatic tumours found in the jaw from other parts of the body should be considered during tumour diagnosis. Moreover, prolonged clinical observation is necessary.

## Ethics statement/confirmation of patients' permission

This study followed the Declaration of Helsinki on medical protocol and ethics and the regional Ethics Review Board of the Peking University School and Hospital of Stomatology approved the study. We obtained patients' permission for publication.

## Conflict of interest

We have no conflicts of interest.

## Acknowledgements

We thank Xiao-Yuan Guan for polishing the paper. We also thank the native English speaking scientists of Elixigen Company (Huntington Beach, California) for editing our manuscript.

## Appendix A. Supplementary data

Supplementary material related to this article can be found, in the online version, at doi:<https://doi.org/10.1016/j.bjoms.2020.06.040>.

## References

1. Foss RD, Ellis GL, Auclair PL. Salivary gland cystadenocarcinomas. A clinicopathologic study of 57 cases. *Am J Surg Pathol* 1996;**20**:1440–7.

2. Seifert G. Histological classification of salivary gland tumours. In: *Histological typing of salivary gland tumors*. World Health Organization. 2nd ed. Berlin: Springer; 1991. p. 1–38.
3. Johnston NJ, Rose DS, Lutterloch MJ. Cystadenocarcinoma of salivary gland presenting as a cystic lesion in the mandible. *Oral Surg Oral Med Oral Pathol Oral Radiol Endod* 2006;**101**:201–4.
4. Auclair PL. Cystadenocarcinoma. In: *World Health Organization classification of tumors: pathology and genetics of head and neck tumors*. 3rd ed. IARC Lyons; 2005. p. 74.
5. Srivanthapoom C, Sittitrai P, Mahanupab P. Central papillary cystadenocarcinoma of the mandible: A case report and review of the literature. *Int J Surg Case Rep* 2014;**5**:330–4.
6. Takei R, Tomihara K, Arai N, et al. Central cystadenocarcinoma of the mandible. *Int J Oral Maxillofac Surg* 2012;**41**:1463–6.
7. Li Y, Li LJ, Huang J, et al. Central malignant salivary gland tumors of the jaw: retrospective clinical analysis of 22 cases. *J Oral Maxillofac Surg* 2008;**66**:2247–53.
8. Madathil J, Kumar NR, Shiny P. Cystadenocarcinoma of the mandible. *Indian J Dent Res* 2018;**29**:396–9.
9. Cavalcante RB, da Costa Miguel MC, Souza Carvalho AC, et al. Papillary cystadenocarcinoma: report of a case of high-grade histopathologic malignancy. *Auris Nasus Larynx* 2007;**34**:259–62.
10. Seethala RR, Stenman G. Update from the 4th Edition of the World Health Organization classification of head and neck tumors: tumors of the salivary gland. *Head Neck Pathol* 2017;**11**:55–67.
11. El-Nagger AK, Grandis JR, Takata T, et al., editors. *WHO classification of head and neck tumors*. 4th ed. Lyon: IARC; 2017.
12. Jewer DD, Boyd JB, Manktelow RT, et al. Orofacial and mandibular reconstruction with the iliac crest free flap: a review of 60 cases and a new method of classification. *Plast Reconstr Surg* 1989;**84**:391–405.
13. Brookstone MS, Huvos AG. Central salivary gland tumors of the maxilla and mandible: A clinicopathologic study of 11 cases with an analysis of the literature. *J Oral Maxillofac Surg* 1992;**50**:229–36.
14. Bouquot JE, Gnepp DR, Dardick I, et al. Intraosseous salivary tissue: Jawbone examples of choristomas, hamartomas, embryonic rests, and inflammatory entrapment : Another histogenetic source for intraosseous adenocarcinoma. *Oral Surg Oral Med Oral Pathol Oral Radiol Endod* 2000;**90**:205–17.
15. Pires FR, Almeida O, De Paes, et al. Central mucoepidermoid carcinoma of the mandible: report of four cases with long-term follow-up. *Int J Oral Maxillofac Surg* 2003;**32**:378–82.
16. Hellquist H, Skalova A. Other carcinomas. In: *Histopathology of the salivary glands*. New York: Springer; 2014. p. 375–427.
17. Larheim TA. Benign jaw tumors and tumorlike conditions. In: *Maxillofacial imaging*. New York: Springer International; 2018. p. 57–70.
18. Larheim TA, Westesson P-LA. Malignant tumors in jaws. In: *Maxillofacial imaging*. New York: Springer International; 2018. p. 171.
19. Skalova A. Cystadenocarcinoma of the salivary glands. In: Volavšek M, editor. *Head and neck pathology*. New York: Springer International; 2016. p. 92–5.
20. Skalova A. Cystadenoma of the salivary glands. In: Volavšek M, editor. *Head and neck pathology*. New York: Springer International; 2016. p. 95–8.
21. Fonseca I. Mucoepidermoid carcinoma of the salivary glands. In: Volavšek M, editor. *Head and neck pathology*. New York: Springer International; 2016. p. 238–41.
22. Fonseca I. Acinic cell carcinoma of the salivary glands. In: Volavšek M, editor. *Head and neck pathology*. New York: Springer International; 2016. p. 7–10.
23. Kneisl JS, Rosenberg AE, Anderson PM, et al. Major salivary glands. In: Edge SB, AJCC, editors. *AJCC cancer staging manual*. 8th ed Springer International; 2017. p. 95.
24. Kneisl JS, Rosenberg AE, Anderson PM, et al. Bone. In: Edge SB, AJCC, editors. *AJCC cancer staging manual*. 8th ed Springer International; 2017. p. 473–7.