

Influence of Placement Depth on Bone Remodeling Around Morse Taper Connection Implant: A Clinical and Radiographic Study in Dogs

Baoxin Huang, DDS, MS*, Huanxin Meng, DDS, PhD*, Muzi Piao, DDS*, Li Xu, DDS, PhD*, Li Zhang, DDS, PhD*, Weidong Zhu, DDS, PhD*

* Department of Periodontology, Peking University School and Hospital of Stomatology, Beijing, China

Background: To evaluate the influence of placement depth on bone remodeling around implants with tapped-in morse taper implant-abutment interface (IAI) and screwed-in morse taper IAI in dogs.

Methods: The second, third, fourth premolars and the first molar in mandibles of 6 beagle dogs were extracted. After 8 weeks, two implants with screwed-in morse taper IAI (SI) and two implants with tapped-in morse taper IAI (TI) were placed in one side of the mandible. Four experimental groups were constituted: SI placed crestally (SIC); TI placed crestally (TIC); SI placed 1.5mm subcrestally (SIS); and TI placed 1.5mm subcrestally (TIS). Healing abutments were connected 12 weeks after implant surgery. Implants and teeth were brushed every second day during the healing period. Clinical and radiographic parameters were recorded at 4, 10 and 16 weeks after second stage surgery.

Results: Differences between SI and TI inserted in same vertical position were not significant for peri-implant probing depth (PPD), clinical attachment level (CAL) and bone resorption ($P>0.05$). Subcrestal placement of both implants had larger PPD and CAL compared to crestal groups. However, distance from IAI to the first bone-implant contact (IAI-fBIC) was lower in subcrestal groups compared to crestal groups (1.27 ± 0.42 mm for SIC vs. 0.46 ± 0.26 mm for SIS, $P<0.05$; 1.36 ± 0.31 mm for TIC vs. 0.78 ± 0.42 mm for TIS, $P<0.05$).

Conclusion: Morse taper IAI configuration had no significant effect on crestal bone resorption. Moreover, subcrestal placement of morse taper IAI had a positive impact on crestal bone preservation around the implant's cervix.

KEY WORDS

Animals; dental implants; radiography; bone resorption; comparative study

Subcrestal placement of two-stage implants in esthetic areas had been recommended in order to get an ideal emergence profile¹⁻². In addition, data from biomechanical analysis had showed that strain levels in peri-implant bone were reduced as the insertion depth of the implant was increased³. However, microgap of implant-abutment interface (IAI) had been implicated as a key factor contributing to peri-implant bone remodeling.

In the past 15 years, microleakage at the IAI had been widely evaluated⁴⁻⁸. Bacteria, fluid and small molecules were capable of passing through the IAI⁴⁻⁶. **Result from clinical study** revealed that periodontopathic microbes inhabited the IAI of two-stage

implant⁹. Furthermore, animal study showed that crestal bone was located about 1.5 to 2mm below the IAI¹⁰. Subcrestal placement of IAI promoted a significantly greater maximum density of inflammatory reaction correlated with bone loss than supracrestal interfaces did¹¹⁻¹². In addition, lower peri-implant crevicular fluid, lower levels of **interleukin-1 beta (IL-1 β)** and **tumor necrosis factor-alpha (TNF- α)** around implant placed supercrestally compared with implant placed crestally were reported recently¹³. Therefore, supercrestal implant was recommended, and pure interference-fit connections or one piece implants may be the suitable alternatives¹².

On the other hand, animal studies using commercially available two-part implants indicated that subcrestal implant may not increase bone loss or jeopardize the position of soft peri-implant tissue¹⁴⁻¹⁵. In recent years, studies using implant with morse taper connection showed conflicting results about the influence of IAI on bone loss around implant¹⁶⁻¹⁹. Jung et al.¹⁶ reported that the greatest bone loss occurred at implants placed 1 mm below the bone crest. In contrast, some studies showed a positive impact on crestal bone preservation of subcrestal implant¹⁸⁻¹⁹. It was important to point out that different type of IAI might perform different pattern of bone loss. Narrower “dish-shaped” defect was observed in implant with morse taper connection compared with implant with butt-joint connection of IAI²⁰⁻²¹.

Freestanding single-tooth implant restoration using implant with tapped-in morse taper (locking-taper) IAI, which had been showed excellent microbial sealing ability in vitro study⁷, seemed a reliable solution to treating posterior edentulism²². Different from some other implants with screwed-in morse taper IAI, it was recommended by manufacturer to **insert** 2 to 3mm subcrestally in clinical practice. However, no data was available about whether different placement depth cause different physiologic response around this type of IAI configuration. Moreover, it was unclear that whether implant with locking-taper IAI would be more favor to placed subcrestally compare with implant with screwed-in IAI.

Therefore, the aim of present study was to evaluate the bone remodeling around implant with tapped-in morse taper connection placed crestally and subcrestally, comparing to implant with screwed-in morse taper connection in canine model.

MATERIALS AND METHODS

Animals

The experimental protocol was approved by the Medical Ethical Committee for Animal Investigations of Peking University Health Science Center in Beijing, China (**No. LA2010-032**). Six beagle dogs, 1-2 years old, weighting 10-12.5kg, were included in the experiment. During the experiment, the dogs were housed individually and fed once per day with soft food and water. All surgical and clinical procedures were performed under general anesthesia, using intravenous sodium pentobarbital (30mg/kg).

Surgical Protocol

At the first stage of the study, the mandibular second, third, fourth premolars and first molars were carefully extracted. Before extraction, the surgical sites were disinfected with 0.12% chlorhexidine solution. Subsequently, 2% lidocaine hydrochloride with epinephrine 1:100,000 was administered as local anesthesia. The teeth were sectioned in the bucco-lingual direction, and the roots were individually extracted to reduce trauma on the bony walls. The flaps were sutured with resorbable 4-0 sutures*. After the surgical procedures, antibiotic (penicillin G procaine 40,000IU/kg intramuscular) and analgesic were administered once every 24 hours for 7 days. During the first week post surgery, the local wound area was carefully cleaned with 0.12% chlorhexidine solution.

Following a healing period of 8 weeks, implant surgery was performed. Twenty-four implants were inserted in one side of the mandible. Two implants with screwed-in morse taper IAI (SI)[†] and two implants with tapped-in morse taper IAI (TI)[‡] were placed. Anterior and posterior positions between implant systems were alternated. Four experimental groups were constituted: SI placed crestally (SIC); TI placed crestally (TIC); SI placed 1.5mm subcrestally (SIS); and TI placed 1.5mm subcrestally (TIS).

One week before the implant surgery, supragingival scaling was administered to remove supragingival calculus. For implant placement, horizontal crestal incisions were made from the distal region of the first premolar to the mesial region of the second molar. Mucoperiosteal flaps were elevated to expose the alveolar bone in the mandibles. The edentulous osseous ridge was carefully flattened with surgical burs under copious irrigation with chilled sterile physiologic saline. Osteotomies for implants were drilled according to recommendation from manufacturers. A distance of approximately 10 mm between dental implant centers was maintained to avoid communication among the bone defects. After that, the implants were inserted. After placement the cover screws and/or plug inserters, flaps were sutured with 4-0 nylon sutures to submerge all implants. Antibiotic and analgesic were administered the same as before. The sutures were removed after 10 days of healing.

After 12 weeks of healing, the implants were surgically uncovered. The second stage surgery was carried out by minimal invasion. Small crestal incisions were performed so that the cover screws and/or plug inserters could be removed and replaced by healing abutments and/or temporary abutments. The heights of healing abutments were selected according to commercial availability. For SI group, 4.5mm×4mm and 4.5mm×6mm were used, respectively, in crestal and subcrestal group. For TI group, 4.0mm×4.5mm and 4.0mm×6.5mm were used, respectively, in crestal and subcrestal group. Special attention was taken to avoid occlusal contact. Rinses with 0.12% chlorhexidine digluconate were applied every second day for the first 10 days after surgery. After that, oral hygiene procedure using a soft toothbrush was performed every second day until the end of experiment.

Clinical Evaluation

Clinical parameters were recorded at 4, 10 and 16 weeks after second stage surgery. The distance from the gingival margin to the bottom of the sulcus/pocket (peri-implant probing depth, PPD) and the distance from fixed point in the abutment shoulder to the bottom of the sulcus/pocket (clinical attachment level, CAL) were measured to the nearest 0.5mm using a periodontal probe[§] at mesial and distal sites per implant. CAL was adjusted by different length of abutment and different distances from abutment shoulder to ridge among groups at the time of implant placement. Clinical measurements included the modified plaque index (mPI)²³ and bleeding index (BI)²⁴ were recorded. All clinical measurements were done by one calibrated examiner.

Radiography

Radiographic templates were fabricated before radiographic evaluation similar to the methods describe by Hermann et al²⁵. Chiefly, customized light-polymerizing acrylic resin records at the cusps of the canine and second molar, respectively, were attached to the individual acrylic resin plane to allow for precise repositioning and stabilization of the radiographic template. Commercial available film holder was rigid to customized plane to get a reproducible and parallel image. Then, an optimum parallel and perpendicular standardized radiographic technique was created to minimize errors of angulation and distortion.

Standardized periapical radiographs were taken with a digital image system^{||} at 10 days after implant placement, and at 0, 4, 10, 16 weeks after second stage surgery (Fig. 1). Exposure parameters were 60kV, 7 mA, and 0.16 seconds at a focus-film distance of 37 cm. The following measurements were performed at mesial and distal sites of each implant (Fig. 2): 1) vertical measurement from the implant–abutment interface (IAI) to the first bone-implant contact (fBIC). In situations where the marginal hard tissue was seen above the IAI, it was still recorded as 0 to avoid introducing any bias in the results. 2) vertical measurement from IAI to the ridge (IAI-Ridge); 3) horizontal bone loss (HBL), horizontal measurement from the ridge to the implant body; 4) Peri-implant bone slope (SLO), angle between a vertical line along the outer implant surface and a line extending along the peri-implant bone defect; and 5) ridge loss, vertical measurement from ridge to IAI at 10 days after implant placement (original ridge) subtract follow-up measurement from ridge to IAI. Measurements were adjusted for distortion using the total length of the implant. Software program^{||} was used to analyze each calibrated image. Radiographic image alignment and analysis were performed by one calibrated examiner.

Statistical Analysis

Standard error of measurement (SE) and Spearman correlation coefficient (CC) for clinical (SE= 0.31mm; CC= 0.889) and radiographic measurements (SE= 0.11mm; CC= 0.983) were calculated to determine intraexaminer reliability²⁶.

The mean values and standard deviations were calculated for all the parameters. Experimental data rows were examined with the Shapiro-Wilk test for normal distribution. If data was not distributed normally, it would be analyzed using the Friedman test and the Wilcoxon test. For the statistical evaluation of the changes within groups over time and the changes among groups, analysis of variance (ANOVA) and Bonferroni's correction for multiple comparisons were used, with all results adjusted for any dog effect. Subsequently for comparisons between groups, data at the last evaluation was used because this presented the final result during the full course of healing. ANOVA was re-applied and comparisons of interest were performed using Bonferroni-adjusted Student t tests. *P* values <0.05 were considered significant. All statistical analyses were performed using statistical software[#].

RESULTS

During the experiment, healing was uneventful in all implants. Clinically healthy peri-implant mucosa was observed around implant at the follow-up examinations (Fig. 1). Although oral hygiene was performed every second day, mean mPI was 1.5 and mean BI was 2.0 at the end of experiment. No statistically significant differences of mPI and BI were found among 4 groups.

Clinical Findings

PPD and CAL among 4 groups at baseline were comparable with the 12-week follow-up evaluation ($P>0.05$) (Fig. 3A and 3B, Table 1). At 16 weeks after second stage surgery, PPD were larger for subcrestal groups compared to crestal groups, and difference of PPD between SIC group and SIS group was significant ($P=0.042$) (Table 2). CAL of subcrestal groups were also larger than crestal groups, but only showed significant different in TI groups (4.3 ± 0.5 mm for TIC vs. 5.3 ± 0.9 mm for TIS, $P=0.023$). Differences of PPD and CAL between TI groups and SI groups inserted in same poison were not significant ($P>0.05$) (Table 2).

Radiographic Findings

Ridge loss and IAI-fBIC among 4 groups were increased for all groups over time (Fig. 3C and 3D, Table 1). A statistical significance was observed for IAJ-fBIC at the end of experiment compared with second stage surgery within all groups except the TIC group ($P<0.05$) (Table 1). No statistically differences were observed for IAI-fBIC between 10 weeks and 16 weeks after second stage surgery within all groups ($P>0.05$). The changes of IAI-fBIC were not significant different among groups ($P>0.05$). At the end of experiment, IAI-fBIC in subcrestal groups was significantly lower than crestal groups ($P<0.05$) (Table 2). IAI in crestal groups were located at the coronal position of ridge, while the IAI in subcrestal groups were located at the apical position of ridge (Table 2). The differences in IAI-Ridge between crestal groups and subcrestal groups were significant ($P<0.05$). Concerning the HBL and SLO, TI groups seemed to lower than SI groups. However, the differences in HBL and SLO were not statistically significant among all groups ($P>0.05$) (Table 2).

DISCUSSION

The purpose of present study was to detect the influence of implant depth and IAI configuration on clinical and radiographic parameters around dental implant. There were several previous studies evaluating the influence of subcrestal placement of morse taper implant on crestal bone loss¹⁶⁻²¹, however, only limited information was available about whether different IAI configurations cause different peri-implant bone reactions²⁰⁻²¹ and no comparative data exist between screwed-in morse taper IAI and tapped-in morse taper IAI from a side-by-side comparison when placing implants with their IAI crestally or subcrestally. The result of present study demonstrated that no significant difference in PPD, CAL, Ridge loss, IAI-fBIC and horizontal bone loss between implant with screwed-in morse taper IAI and implant with tapped-in morse taper IAI when both implants were placed crestally or subcrestally under unloading condition. Subcrestal groups had lower IAI-fBIC and higher PPD compared to the crestal groups.

In present study, subcrestal groups had low value of IAI-fBIC (0.46mm for screwed-in IAI, 0.78mm for tapped-in IAI). The bone loss encountered in the implants with screwed-in IAI was comparable to that encountered in previous animal study by Welander et al.¹⁷, who placed the IAI of the same implant system 2 mm subcrestally, and found that IAI-fBIC of the control implant was 0.37mm. Low value of IAI-fBIC in subcrestal groups was also comparable to other earlier studies using implants with screwed-in morse taper IAI under loading and immediately loaded conditions^{16, 18}. However, higher amount of bone resorption about 1.26mm in the subcrestal morse group was reported by Weng et al.²¹ This discrepancy could be from the influence of implant surface. Morse taper implant used in Weng's study had 1.5 mm smooth collar design, while implants with rough collar design were used in present study. It had been reported that bone tissue favors rough implant surfaces compared to relatively smooth titanium surfaces²⁷⁻²⁸.

The reason for low value of IAI-fBIC in subcrestal groups may be partly explained by the sealing ability of morse taper connection which prevent or minimize the bacterial leakage along the conical interface. In the studies of Brogini et al¹¹⁻¹², microgap of IAI about 50 μ m, which acted as a bacterial reservoir, was responsible for bone loss¹². In contrast, the capacity of the locking-taper IAI to prevent the invasion of oral microorganisms was evaluated by Dibart et al.⁷, who concluded that the conical contact between implant and abutment provided by the locking-taper design was hermetic with regard to bacterial invasion even though a 0.5 mm microgap at the prosthetic interface. Another in vitro study was conducted by Aloise et al.⁸ recently, in which *S. sanguinis* II was inoculated in implants with locking-taper IAI and screwed-in morse taper IAI under anaerobic conditions for longer time (14 days), showed that the frequency of bacterial leakage along IAI was only 20% of each type of IAI. This finding may also be contributed to the IAI design with platform switching. The concept of platform switching²⁹, which means that the abutment with narrower diameter was connected to the implant, had been suggested decrease crestal bone loss by shifting the IAI away

from bone crest to reduce the influence of bacterial leakage from IAI and by shifting the stress concentration away from the dense cortical bone around bone-implant interface. Limited bone remodeling around implant with platform switching which was placed subcrestally had been reported in clinical studies^{19,30}.

In this study, IAI-fBIC in implants of crestal group were, respectively, 1.27mm and 1.36mm for screwed-in IAI group and tapped-in IAI group. It was also lower than bone loss obtained by Weng et al.²¹ who reported 2.08mm for the same parameter in their crestal Morse group. However, better IAI-fBIC of about 0.85mm for their crestal submerged implants with screwed-in IAI was found by Abrahamsson et al.³¹. The reasonable explanation was that several factors such as IAI, implant surface, formation of biological width and surgical trauma may contribute to bone remodeling around crestal placement implant³²⁻³³. In present study, ridge loss during implant placement to second stage surgery, which might be chiefly caused by surgical trauma, was 0.38mm to 0.78mm (Fig. 3C). High value of IAI-fBIC in crestal groups had established at the time of second stage surgery and the change of IAI-fBIC from second stage surgery to 16 weeks later among 4 groups was no significant difference (Table 1, Fig. 3D).

It should be pointed out the clinical implication of the present study. Although different clinical recommendations were given by manufacturers for two implant systems used in present study, the results of the present study demonstrated that two kinds of IAI configuration had no significant difference in clinical and radiographic parameters. Limited IAI-fBIC in subcrestal group might not be a key factor in the success of regular implant. But for short implant, improvement of bone-implant contact might be important for getting a predictable long term result. Furthermore, IAI in subcrestal groups were located at the apical position of ridge, which was benefit for avoiding metal exposure. **Therefore, according to the present results, appropriate subcrestal placement of implant with Morse taper IAI was recommended.** However, the optimal position related to the crest when subcrestally placed the implant remained further evaluation.

Although low value of IAI-fBIC around subcrestal implant was also reported by several studies aforementioned, different recommendations were raised in different studies. **For instance**, in study of Jung et al.¹⁶, bone loss was measured from reference line representing ridge at the time of implant placement to fBIC at the end of experiment, and the result showed that the greatest bone loss occurred at implants placed 1 mm below the bone crest. Another reported by Barros et al.¹⁸, who measured the value of Ridge-IAI and regarded it as crestal bone resorption, showed that the crestal bone resorptions of subcrestal groups were significantly lower than those of crestal groups. However, some other studies proposed that crestal bone loss around subcrestal implant was identified as IAI-fBIC^{19,30}. The apparent discrepancies might partly be explained by the difference in measurement techniques. It seemed that a single parameter could not totally represent bone response around subcrestal implant, three major parameters were suggested for evaluating the bone morphology around subcrestal implant: IAI-fBIC, representing bone-to-implant contact around implant; IAI-Ridge, revealing the relative position between top of implant and ridge, which is

critical to avoid metal exposure; and HBL, reflecting the wide of intrabony defect, which is important for further ridge prevention.

Another interesting result in present study was that greater PPD and CAL were recorded in subcrestal groups than in crestal groups. Similar result was reported by Pontes et al¹⁵, in which implant with butt-joint connection of IAI was used. It was in accordance with the results of the animal study by Todescan et al.¹⁴ who reported a longer epithelium and connective tissue were observed around implants placed 1 mm below crestal bone compared to those placed at the crestal bone level. Moreover, in present study, PPD and CAL values were stable from 4 weeks after second stage surgery to the end of experiment. These clinical findings implicated that the absolute values of PPD and CAL might not be treated as a single parameter for evaluating the clinical status of implant, since it was **influenced** by implant depth and it was not in correlated with the bone loss (IAI-fBIC). The establishment of baseline PPD and CAL values was important for allowing comparison with future examine. The stability of these results should be determined over a longer period.

It should be mentioned that the soft and hard tissue change around implants in present study was evaluated under unloading condition. Although no crestal bone loss after normal loading had been showed in previous study³⁴, different micromechanical stability of IAI and different stress distributing pattern might cause different bone remodeling around implant. Clinical study with longer healing period and under loading condition should be conducted in future investigations to confirm the present results and evaluate their clinical significance.

CONCLUSIONS

Within the limits of this study, it was concluded that morse tapper IAI configuration had no significant effect on crestal bone resorption. Moreover, absolute values of PPD and CAL might increase following implant placed subcrestally, which implied the importance of establishing baseline PPD and CAL for evaluating the clinical status of implant. **Furthermore, subcrestal placement of morse tapper IAI had a positive impact on crestal bone preservation around the implant's cervix.**

ACKNOWLEDGMENTS

The authors would like to thank Wenge Ren, Department of Oral Radiology, Peking University School and Hospital of Stomatology, for his assistance with taking periapical radiographs. This project was partly supported by grants from Bicon Dental Implant, Boston, MA, USA. The authors are grateful to Bicon Dental Implant for providing Bicon implants utilized for this study. All authors report no conflicts of interest related to this study.

SOURCES OF SUPPORT:

This project was partly supported by Bicon Dental Implant, **Boston, MA, USA**. **Bicon** implants utilized in this study were provided by Bicon Dental Implant.

CONFLICT OF INTEREST:

All authors report no conflicts of interest related to this study.

REFERENCES

1. Buser D, von Arx T. Surgical procedures in partially edentulous patients with ITI implants. *Clin Oral Implants Res* 2000;11:83-100.
2. Novaes AB, Barros RRM, Muglia VA, Borges GJ. Influence of interimplant distances and placement depth on papilla formation and crestal resorption: a clinical and radiographic study in dogs *J Oral Implantol* 2009;35:18-27.
3. Chou HY, Muftu S, Bozkaya D. Combined effects of implant insertion depth and alveolar bone quality on periimplant bone strain induced by a wide-diameter, short implant and a narrow-diameter, long implant. *J Prosthet Dent* 2010;104:293-300.
4. Jansen VK, Conrads G, Richter EJ. Microbial leakage and marginal fit of the implant-abutment interface. *Int J Oral Maxillofac Implants* 1997;12:527-540.
5. Gross M, Abramovich I, Weiss EI. Microleakage at the abutment-implant interface of osseointegrated implants: a comparative study. *Int J Oral Maxillofac Implants*. 1999;14:94-100.
6. Coelho PG, Sudack P, Suzuki M, Kurtz KS, Romanos GE, Silva N. In vitro evaluation of the implant abutment connection sealing capability of different implant systems. *J Oral Rehabil* 2008;35:917-924.
7. Dibart S, Warbington M, Su MF, Skobe Z. In vitro evaluation of the implant-abutment bacterial seal: The locking taper system. *Int J Oral Maxillofac Implants* 2005;20:732-737.
8. Aloise JP, Curcio R, Laporta MZ, Rossi L, da Silva AM, Rapoport A. Microbial leakage through the implant-abutment interface of morse taper implants in vitro. *Clin Oral Implants Res* 2010;21: 328-335
9. Callan DP, Cobb CM, Williams KB. DNA probe identification of bacteria colonizing internal surfaces of the implant-abutment interface: a preliminary study. *J Periodontol* 2005;76:115-120.
10. Hermann JS, Cochran DL, Nummikoski PV, Buser D. Crestal bone changes around titanium implants. A radiographic evaluation of unloaded nonsubmerged and submerged implants in the canine mandible. *J Periodontol* 1997;68:1117-1130.
11. Broggin N, McManus LM, Hermann JS, et al. Persistent acute inflammation at the implant-abutment interface. *J Dent Res* 2003;82:232-237.
12. Broggin N, McManus LM, Hermann JS, et al. Peri-implant inflammation defined by the implant-abutment interface. *J Dent Res* 2006;85:473-478.
13. Boynuegri AD, Yalim M, Nemli SK, Erguder BI, Gokalp P. Effect of different localizations of microgap on clinical parameters and inflammatory cytokines in peri-implant crevicular fluid: a prospective comparative study. *Clin Oral Investig* Accessed: Jan 7 2011.
<http://www.springerlink.com/content/e138471322851032/>

14. Todescan FF, Pustiglioni FE, Imbrunite AV, Albrektsson T, Gioso M. Influence of the microgap in the peri-implant hard and soft tissues: A histomorphometric study in dogs. *Int J Oral Maxillofac Implants* 2002;17:467-472.
15. Pontes AEF, Ribeiro FS, da Silva VC, et al. Clinical and radiographic changes around dental implants inserted in different levels in relation to the crestal bone, under different restoration protocols, in the dog model. *J Periodontol* 2008;79:486-494.
16. Jung RE, Jones AA, Higginbottom FL, et al. The influence of non-matching implant and abutment diameters on radiographic crestal bone levels in dogs. *J Periodontol* 2008;79:260-270.
17. Welander M, Abrahamsson I, Berglundh T. Subcrestal placement of two-part implants. *Clin Oral Implants Res* 2009;20:226-231.
18. Barros RRM, Novaes AB, Jr., Muglia VA, Iezzi G, Piattelli A. Influence of interimplant distances and placement depth on peri-implant bone remodeling of adjacent and immediately loaded Morse cone connection implants: a histomorphometric study in dogs. *Clin Oral Implants Res* 2010;21:371-378.
19. Donovan R, Fetner A, Koutouzis T, Lundgren T. Crestal bone changes around implants with reduced abutment diameter placed non-submerged and at subcrestal positions: a 1-year radiographic evaluation. *J Periodontol* 2010;81:428-434.
20. Weng D, Nagata MJH, Bell M, Bosco AF, Melo LGNd, Richter E-J. Influence of microgap location and configuration on the periimplant bone morphology in submerged implants. An experimental study in dogs. *Clin Oral Implants Res* 2008;19:1141-1147.
21. Weng D, Nagata MJ, Bell M, de Melo LG, Bosco AF. Influence of Microgap Location and Configuration on Peri-implant Bone Morphology in Nonsubmerged Implants: An Experimental Study in Dogs. *Int J Oral Maxillofac Implants* 2010;25:540-547.
22. Muftu A, Chapman RJ. Replacing posterior teeth with freestanding implants: Four-year prosthodontic results of a prospective study. *J Am Dent Assoc* 1998;129:1097-1102.
23. Mombelli A, van Oosten MA, Schurch E, Jr., Land NP. The microbiota associated with successful or failing osseointegrated titanium implants. *Oral Microbiol Immunol* 1987;2(4):145-151.
24. Mazza JE, Newman MG, Sims TN. Clinical and antimicrobial effect of stannous fluoride on periodontitis. *J Clin Periodontol* 1981;8:203-212.
25. Hermann JS, Schoolfield JD, Nummikoski PV, Buser D, Schenk RK, Cochran DL. Crestal bone changes around titanium implants: A methodologic study comparing linear radiographic with histometric measurements. *Int J Oral Maxillofac Implants* 2001;16:475-485.
26. Araujo MWB, Hovey KM, Benedek JR, et al. Reproducibility of probing depth measurements using a constant-force electronic probe: Analysis of inter- and intraexaminer variability. *J Periodontol* 2003;74:1736-1740.
27. Hammerle CH, Bragger U, Burgin W, Lang NP. The effect of subcrestal placement of the polished surface of ITI implants on marginal soft and hard tissues. *Clin Oral Implants Res* 1996;7:111-119.

28. Schwarz F, Herten M, Bieling K, Becker J. Crestal bone changes at nonsubmerged implants (Camlog) with different machined collar lengths: a histomorphometric pilot study in dogs. *Int J Oral Maxillofac Implants* 2008;23:335-342.
29. Lazzara RJ, Porter SS. Platform switching: A new concept in implant dentistry for controlling postrestorative crestal bone levels. *Int J Periodontics Restorative Dent* 2006;26:9-17.
30. Veis A, Parissis N, Tsirlis A, Papadeli C, Marinis G, Zogakis A. Evaluation of peri-implant marginal bone loss using modified abutment connections at various crestal level placements. *Int J Periodontics Restorative Dent* 2010;30:609-617.
31. Abrahamsson I, Berglundh T, Moon IS, Lindhe J. Peri-implant tissues at submerged and non-submerged titanium implants. *J Clin Periodontol.* 1999;26:600-607.
32. Berglundh T, Lindhe J. Dimension of the periimplant mucosa - Biological width revisited. *J Clin Periodontol.* 1996;23:971-973.
33. Oh TJ, Yoon Y, Misch CE, Wang HL. The causes of early implant bone loss: Myth or science? *J Periodontol* 2002;73:322-333.
34. Berglundh T, Abrahamsson I, Lindhe J. Bone reactions to longstanding functional load at implants: an experimental study in dogs. *J Clin Periodontol* 2005;32:925-932.

Correspondence: Dr. Huanxin Meng, Department of Periodontology, Peking University School and Hospital of Stomatology, 22 Zhongguancun Nandajie, Haidian District, 100081, Beijing, P.R. China. Fax: 86-10-62173402; e-mail: kqhxmeng@bjmu.edu.cn.

Submitted October 17, 2011; accepted for publication November 25, 2011.

Figure 1

Clinical and radiographic images of four groups at implant placement (1A, 1B); second stage surgery (1C, 1D); 4 weeks after second stage surgery (1E, 1F); 10 weeks after second stage surgery (1G, 1H); and 16 weeks after second stage surgery (1I, 1J).

Figure 2

Schematic representation of the landmarks for radiographic parameters measured: (1) Original ridge: ridge at the time of implant placement; (2) Ridge: ridge at the time of evaluation; (3) IAI: implant-abutment interface; (4) fBIC: first bone-implant contact; (5) HBL: horizontal bone loss; (6) SLO: peri-implant bone slope.

Figure 3

Plotting of means (n=6) of peri-implant probing depth (PPD) (3A), clinical attachment level (CAL) (3B), Ridge loss (3C) and IAJ-fBIC (3D) for all groups over time after second stage surgery.

SIC: screwed-in morse taper IAI placed crestally; SIS: screwed-in morse taper IAI placed subcrestally; TIC: tapped-in morse taper IAI placed crestally; TIS: tapped-in morse taper IAI placed subcrestally.

Table 1. Data (mm; mean \pm SD) from the clinical and radiographic analysis of implants over time after

Parameters	0 weeks	4 weeks	10 weeks	16 weeks	Change	P
PPD					16 -4 weeks	
SI crestal	-	2.5 \pm 0.5	2.5 \pm 0.4	2.6 \pm 0.3	0.0 \pm 0.5	NS
SI subcrestal	-	3.3 \pm 0.6	3.0 \pm 0.3	3.2 \pm 0.3	-0.1 \pm 0.7	NS
TI crestal*	-	2.1 \pm 0.1	2.1 \pm 0.3 a	2.4 \pm 0.3 a	0.4 \pm 0.3	a
TI subcrestal	-	2.4 \pm 0.4	2.5 \pm 0.4	2.8 \pm 0.4	0.4 \pm 0.5	NS
P					NS	
CAL					16 -4 weeks	
SI crestal	-	5.3 \pm 0.7	5.0 \pm 0.6	5.0 \pm 0.5	-0.3 \pm 0.4	NS
SI subcrestal	-	5.7 \pm 0.6	5.3 \pm 0.5	5.3 \pm 0.5	-0.5 \pm 0.7	NS
TI crestal	-	4.0 \pm 0.5	4.1 \pm 0.7	4.3 \pm 0.5	0.3 \pm 0.6	NS
TI subcrestal	-	5.1 \pm 0.5	5.4 \pm 0.9	5.3 \pm 0.9	0.2 \pm 0.8	NS
P					NS	
Ridge loss					16 -0 weeks	
SI crestal	0.38 \pm 0.37 b	0.60 \pm 0.49	0.72 \pm 0.44	0.83 \pm 0.39 b	0.46 \pm 0.43	b
SI subcrestal	0.57 \pm 0.36 c	0.70 \pm 0.27	0.79 \pm 0.24	0.90 \pm 0.29 c	0.34 \pm 0.29	c
TI crestal*	0.62 \pm 0.21 d	0.66 \pm 0.30 e	0.81 \pm 0.27de	0.83 \pm 0.31	0.21 \pm 0.29	d e
TI subcrestal	0.78 \pm 0.25fg	0.95 \pm 0.27	1.05 \pm 0.26 f	1.13 \pm 0.31 g	0.36 \pm 0.21	f g
P					NS	
IAJ-fBIC					16 -0 weeks	
SI crestal	0.68 \pm 0.34hi	0.88 \pm 0.36j	1.07 \pm 0.56h	1.27 \pm 0.42ij	0.60 \pm 0.32	h i j
SI subcrestal	0.14 \pm 0.16 k	0.32 \pm 0.23	0.39 \pm 0.24	0.46 \pm 0.26 k	0.32 \pm 0.34	k
TI crestal	1.11 \pm 0.21	1.11 \pm 0.32	1.22 \pm 0.24	1.36 \pm 0.31	0.25 \pm 0.29	NS
TI subcrestal	0.35 \pm 0.30 l	0.57 \pm 0.37	0.56 \pm 0.34	0.78 \pm 0.42 l	0.44 \pm 0.22	l
P					NS	

second stage surgery

PPD: peri-implant probing depth; CAL: clinical attachment level; Ridge loss: ridge change from implant placement to follow-up evaluation after second stage surgery; IAI-fBIC: distance from IAI to first bone-implant contact. SI: screwed-in morse taper IAI; TI: tapped-in morse taper IAI.

ANOVA test was used to analyze data which was distributed normally. Pairwise comparisons were performed using Bonferroni-adjusted Student t tests.

* Data was not distributed normally. Significant different was obtained from Friedman Test ($P < 0.05$), Wilcoxon test was used for compared each other.

NS: not significant different.

Identical letters indicate statistically significant differences ($P<0.05$)

Table 2. Data (mm; mean \pm SD) from the clinical and radiographic analysis of implants at 16 weeks after second stage surgery

parameters		crestal	subcrestal	P
PPD*	SI	2.6 \pm 0.3	3.2 \pm 0.3	0.042
	TI	2.4 \pm 0.3	2.8 \pm 0.4	NS
	P	NS	NS	
CAL	SI	5.0 \pm 0.5	5.3 \pm 0.5	NS
	TI	4.3 \pm 0.5	5.3 \pm 0.9	0.023
	P	NS	NS	
Ridge loss	SI	0.83 \pm 0.39	0.90 \pm 0.29	NS
	TI	0.83 \pm 0.31	1.13 \pm 0.31	NS
	P	NS	NS	
IAI- Ridge[†]	SI	-0.80 \pm 0.51	0.61 \pm 0.21	<0.001
	TI	-0.89 \pm 0.44	0.25 \pm 0.41	<0.001
	P	NS	NS	
IAJ-fBIC	SI	1.27 \pm 0.42	0.46 \pm 0.26	0.001
	TI	1.36 \pm 0.31	0.78 \pm 0.42	0.020
	P	NS	NS	
LBL	SI	0.70 \pm 0.29	0.87 \pm 0.28	NS
	TI	0.43 \pm 0.40	0.54 \pm 0.36	NS
	P	NS	NS	
SLO($^{\circ}$)*	SI	41.42 \pm 15.40	40.46 \pm 9.03	NS
	TI	27.47 \pm 15.58	30.67 \pm 17.32	NS
	P	NS	NS	

PPD: peri-implant probing depth; CAL: clinical attachment level; Ridge loss: ridge change from implant placement to follow-up evaluation after second stage surgery; IAI-Ridge: distance from implant-abutment interface to Ridge; IAI-fBIC: distance from IAI to first bone-implant contact; HBL: horizontal bone loss; SLO: peri-implant bone slope. SI: screwed-in morse taper IAI; TI: tapped-in morse

taper IAI.

ANOVA test was used to analyze data which was distributed normally. Pairwise comparisons were performed using Bonferroni-adjusted Student t tests.

NS: not significant different.

* Data was not distributed normally. Friedman test and Wilcoxon test were used.

[†] Negative value means ridge at the apical position of IAI.

* Vicryl, Ethicon, Langhorne, PA, USA.

[†] OsseoSpeed, 3.5mm \times 8mm, Astra Tech Dental, Mölndal, Sweden.

[‡] Integra-CP, 3.5mm \times 8mm, Bicon Dental Implant, Boston, MA, USA.

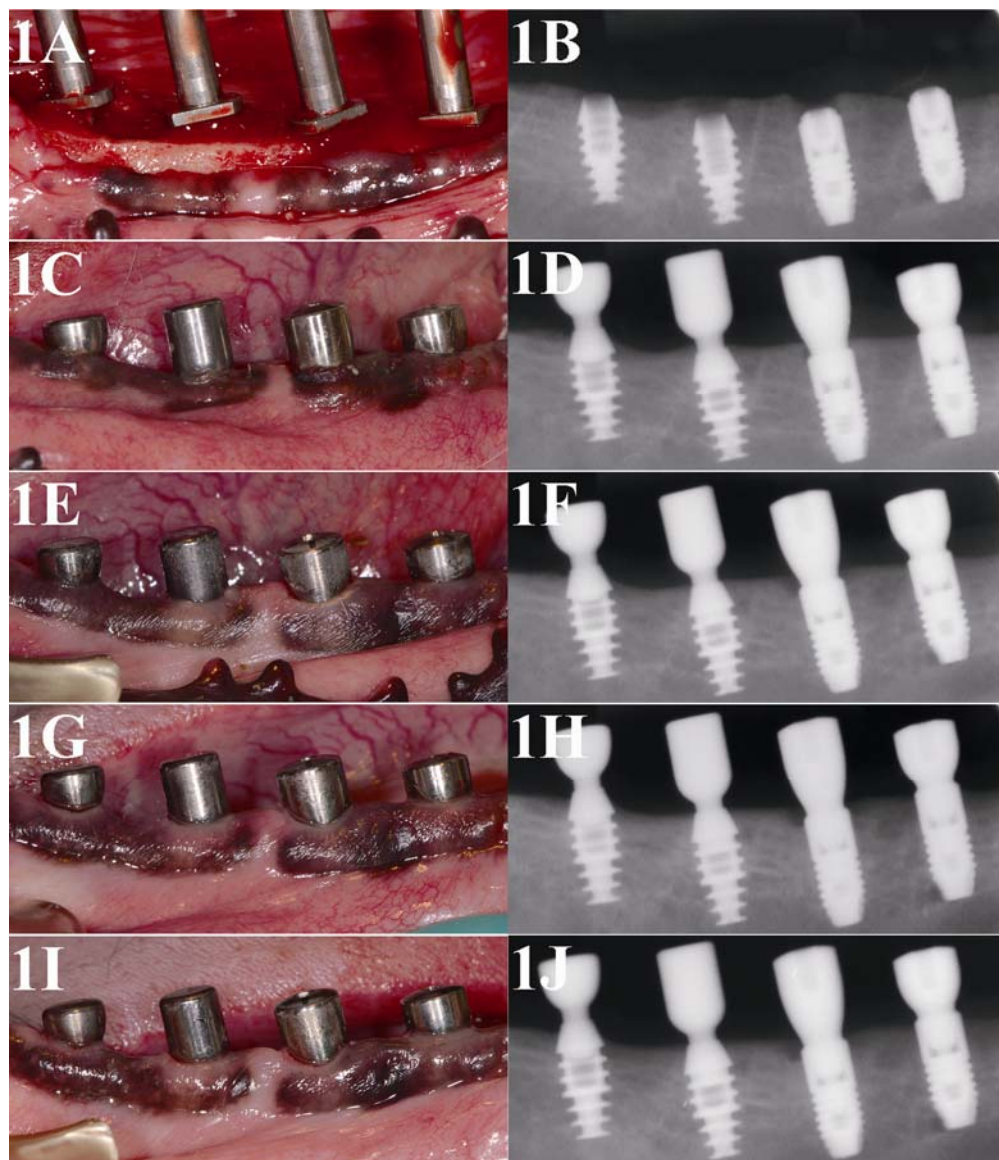
§ North Carolina, Hu-friedy, Chicago, IL, USA.

|| Digora, Soredex, Helsinki, Finland.

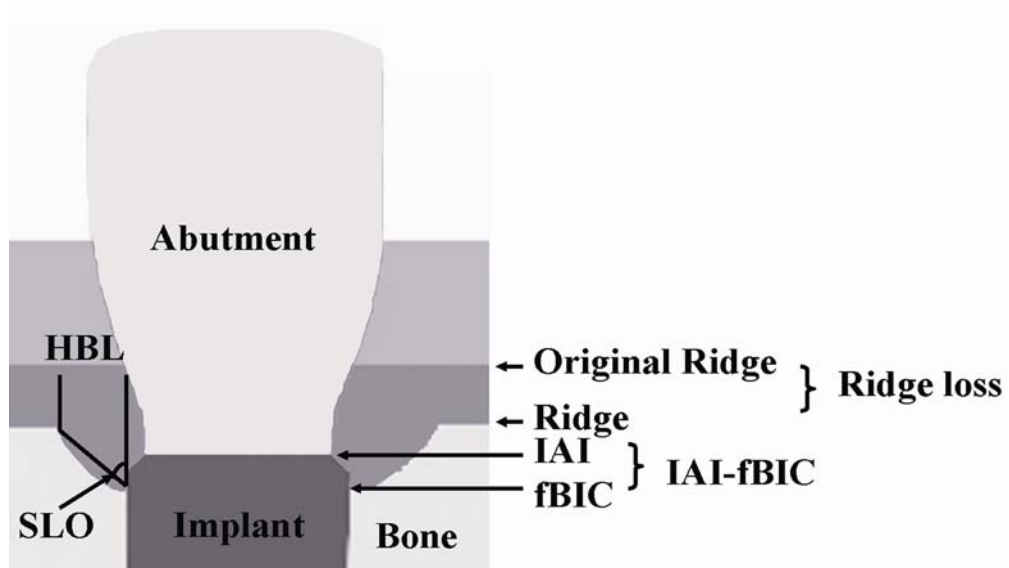
¶ Image J 1.44n, National Institutes of Health, Bethesda, MD, USA.

SPSS 11.5, SPSS, Chicago, IL, USA.

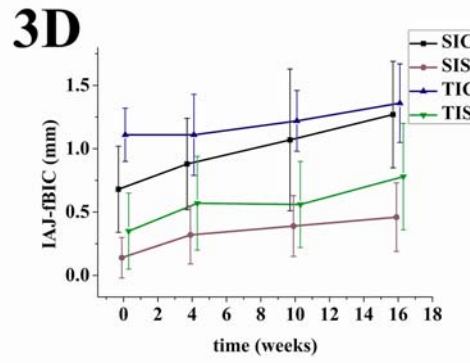
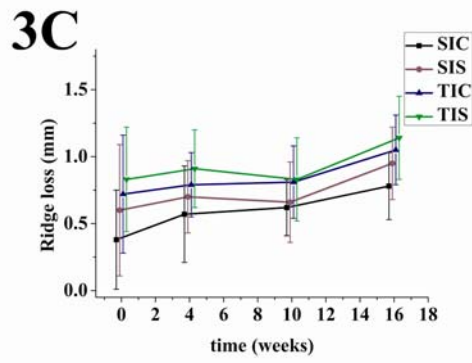
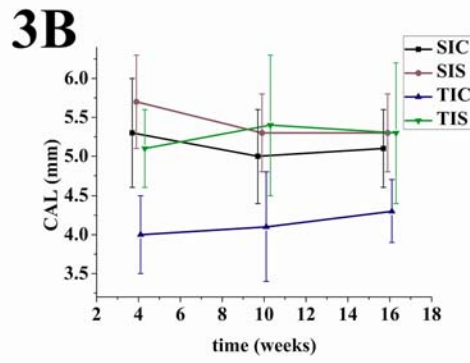
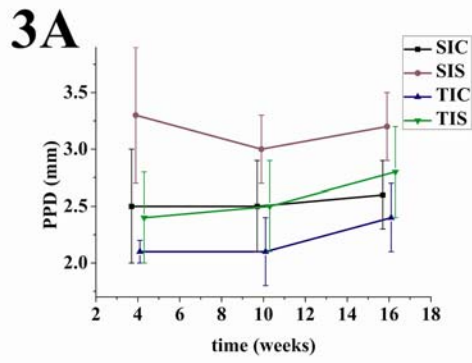
unedited



Un



unedited



unedit